INDIAN JOURNAL OF DENTAL ADVANCEMENTS
Journal homepage: www.nacd.in

CASE REPORT

Prosthetic rehabilitation of a 7 year old child with Hypohidrotic Ectodermal Dysplasia

Rani TS[1], Reddy RE[2], Manjula M[3], Sreelakshmi N[4]

Dept. of Pedodontics, Kamineni Institute of Dental Sciences, Narketpally, Andhra Pradesh, India

Reader[1]
Professor&HOD[2]
Professor[3&4]

Article Info
Received: 21st July, 2009
Review Completed: 25th August, 2009
Accepted: 20th September, 2009
Available Online: 18th January, 2010

Abstract:

Hypohidrotic ectodermal dysplasia is an uncommon disorder of tissues derived from ectoderm, characterized by the triad of hypohidrosis and hypodontia, which form the essential features of the syndrome 1. A case of a 7 year old child with hypohidrotic ectodermal dysplasia with oligodontia and marked resorption of alveolar ridges is presented. Prosthetic rehabilitation with removable acrylic prosthesis done on achieving excellent esthetics, functionality and adaptation.

Key words: ***Hypohidrotic ectodermal dysplasia, Partialanodontia, Prosthetic rehabilitation***

INTRODUCTION

Hypohidrotic ectodermal dysplasia is a rare genetic disorder characterized by faulty development of ectodermal structure.[2] Freire - Maia[3] defined ectodermal dysplasia as any syndrome that demonstrated at least two of the following features: trichodysplasia (abnormal hair), hypodontia / anodontia (abnormal dentition), palmoplantar hypohidrosis (abnormal or missing sweat glands), onychodysplasia (abnormal nails). Ectodermal dysplasia is a relatively rare disorder, with a frequency varying between 1:10,000 and 1:1,00,000 live births and is more frequent in males.[4] These patients present with a soft, smooth, thin dry skin.[5]

Diminished or missing sweat glands cause heat intolerance and hyperpyrexia. The sebaceous glands may also be diminished or totally absent. Spoon shaped nails may be seen in rare cases. Xerostomia may occur when there is hypoplasia of salivary glands. Some cases may demonstrate a high palatal arch or even a cleft palate.[6] Most reported cases have dealt with oligodontia. The teeth when present often have conical crowns.

CASE REPORT

A 7 year old girl presented with complaint of missing teeth to the Department of Pedodontics and Preventive Dentistry. She came with her father who gave history of uneruption of deciduous teeth except for two teeth in the upper jaw which were erupted at 3 years of age. On general examination, her hair was fine, sparsely distributed, thinly covering the scalp and the skin was found to be fine smooth and dry, and nails revealed no abnormality. She had characteristic facies with prominence of frontal and temporal regions of the scalp, saddle nose, large ears (megalo - pinna), protuberant lips and depressed central portion of face.

Email for correspondence:
tabitha_rani@yahoo.com

Cutaneous examination revealed thin sparsely distributed hair over the scalp and eyebrows. There was hyper pigmentation on the nose and around the eyes. There was no history of consanguinity among parents and none of the family members had history of missing teeth. The parents gave a medical history of repeated respiratory tract infections and also about heat intolerance at elevated temperatures.

Intra oral examination revealed bone atrophy of maxillary and mandibular alveolar ridges. Mandibular arch was completely edentulous and maxillary arch had two short, conical, pointed right and left primary canines (Fig. 1).

PROSTHETIC REHABILITATION:

Prosthetic rehabilitation in children with HED depends on the degree of anodontia. In complete anodontia the treatment would comprise of complete dentures[7], either conventional or implant supported. In patients with partial anodontia, removable/fixed partial dentures and overdentures[8] may be considered.[9]

The parents were explained the line of treatment which consisted of lower complete and upper partial acrylic prosthesis using steel retainers on the teeth present and also about the existing maxillary primary canines. This design allows modification to be made as and when necessary as well as providing reasonable esthetic result, an acceptable masticatory function on complementing the lack of dentition.

The child was familiarized with the materials to be used in the first appointment. In the second appointment, two primary canines which were conical in shape were built in the shape of permanent canines using light cure composite resin in order to place the retainers of the partial denture and also to simulate the teeth which were placed in the prosthesis (Fig. 2). Impressions were made using reversible hydrocolloid for the lower arch and irreversible hydrocolloid for the upper arch and casts were poured with dental stone. A wax spacer was adapted over the non-stress bearing areas especially where the ridges were thin and sharp. Acrylic custom trays were prepared. The acrylic trays were then border moulded using green sick compound and the final impressions were made using Zinc Oxide Eugenol impression paste.

Occlusal rims were fabricated. The maxillary rim was adjusted for the lip support, esthetics and phonetic requirement. The mandibular rim was next adjusted and the jaw relations were obtained using a modeling wax. The maxillo-mandibular record was verified and then later was transferred to an articulator. Selection of teeth for children and adolescents requires more attention as the commercially available moulds do not satisfy esthetic requirements in most cases; obviously because these moulds mimic adult dentitions.[9] Proper shade selection of acrylic teeth was done and trimmed to the approximate dimensions of the deciduous teeth and teeth setting were done. Try-in was checked for retention, esthetics and phonetics. Dentures were processed using heat cure acrylic resin (Fig. 3) and inserted (Fig. 4). Post insertion instructions on denture wear, functions of speech, mastication, hygiene and maintenance were given.

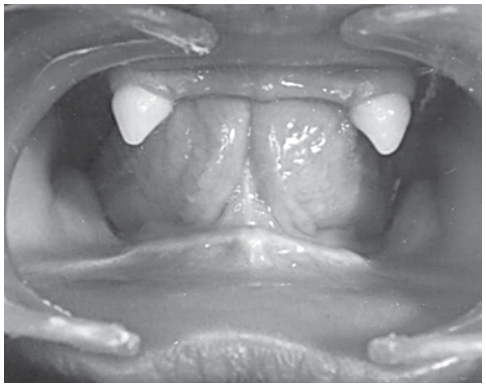

Fig. 1 Conical shaped primary canines

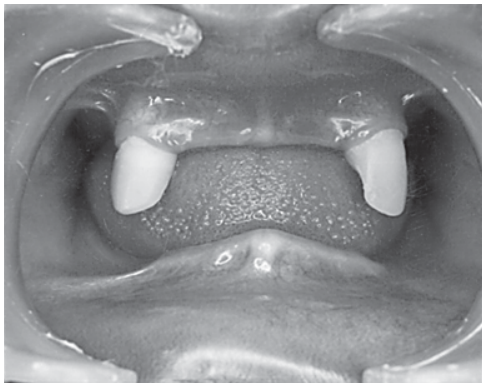

Fig. 2 Composite build up done on canines

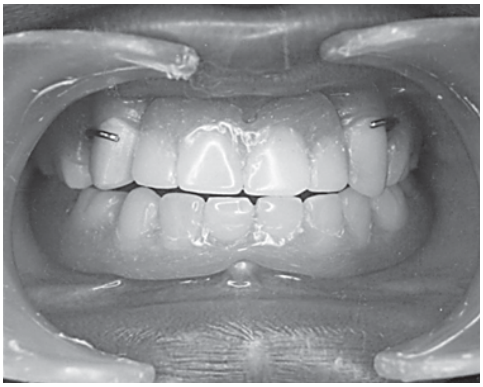

Fig. 3 After insertion of removable acrylic prosthesis

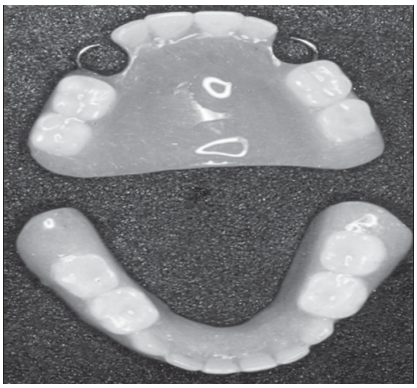

Fig. 4 Lower complete denture, upper removable partial denture

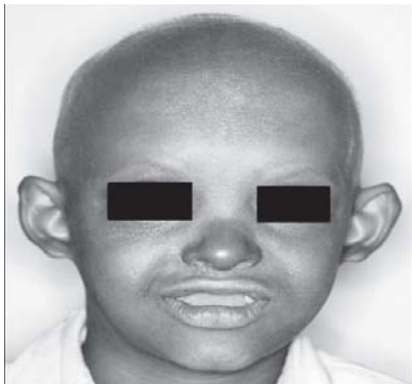

Fig. 5 Pre-Op

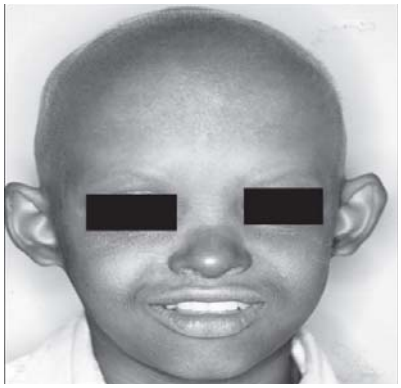

Fig. 6 Post-Op

Patient was recalled after 24 hrs of denture insertion for the post insertion checkup. Periodic checkups were advised, approximately once in every six months to make small adjustments and modifications to the given prosthesis.

DISCUSSION

The hypohidrotic ectodermal dysplasia, otherwise called Christ- seimens- Touraine syndrome (X – linked form) described by Thurnam in 1848.[10]

The Ectodermal Dysplasia (ED) is a group of inherited disorder that share in common developmental defects involving at least two of the major structure classically hold to derive from the embryonic ectoderms – hair, teeth, nails, sweat glands. Orally, the disease is characterized by hypodontia, oligodontia or anodontia, which can, moreover, affect both the maxilla and mandible, delayed eruption, malformed teeth producing a small, pointed conical appearance and resorption or atrophy of the alveolar border, thus complicating the fundamental rehabilitation procedure in these patients.

Treatment of a child with ED requires a multidisciplinary approach and knowledge of behavioral management of the pediatric patient. The ED child can be rehabilitated using composite build up, crowns, fixed prosthesis, over dentures, removable prosthesis or implants depending on the dentition present.

Treatment should be aimed at maintaining the dentition present and alveolar ridges as these structures have to support the denture prosthesis for a life time. Treatment should be commenced as soon as possible to avoid possible resorption and atrophy of the alveolar ridges, and to control the vertical dimension, which can be severely affected by the total or partial lack of teeth.[11]

The prosthetic treatment should be carried out on an individual basis, aimed always towards providing good occlusal stability. It also aids in phonation and mastication. These factors instill greater self confidence in the child and help him gain acceptance. [11]

Different authors have proposed different rehabilitation possibilities for these patients. In general, almost all agree in recommending the use of removable prosthesis during the first stages of growth allowing the adjustment of the vertical dimension until the patient finishes growth.[12-16] When a more stable and fixed situation is established and the possibility of implant treatment can be considered. Till and Marques[17] recommend that the initial dentures should be delivered before the child begins school, so that the child has time to adapt to it. A well fitting set of dentures restores the facial appearance to a great extent.

SUMMARY

The use of partial acrylic prosthesis is an interesting and practical alternative that provides a relatively quick, easy, acceptable and economical solution to this functional and esthetic oral rehabilitation in patients with pronounced edentulism. It helps to normalize the function of masticatory and perioral muscles consequently the growth pattern of basal bones and gives psychological boost to the self – image of the child.[18] Early rehabilitation of children with ED will go a long way in helping them interact normally with their peers.[7] But one must remember that any form of restoration or prosthesis should provide dentition confirming with the age of the patient.

REFERENCES:

1. Clarke A. Hypohydrotic ectodermal dysplasia. J Med Genet 1987; **24 (11)**: 659-663.
2. Soloman LH, kenes EJ. The ectodermal dysplasia. Arch dermatol 1980; **116**: 259 -269.
3. Freire – maia N. Ectodermal hysplasia. Hum Hered 1971; **21**:309.
4. Della valle D, Chevitarese. AB, Maia LC Farinhas JA. Alternative rehabilitation treatment for a patient with ectodermal dysplasia. J Clin Pediatr Dent 2004; **28 (2)**: 103-106.
5. Shafer WG, Hine MK, Levy BM. A text book of oral pathology. 4th ed. W. B. Saunders company, 1983:807,
6. Rowan DM. Scalp dermatitis, ectodermal dysplasia and cleft lip and palate: rapphodgkin or AEC syndrome. Australia journal of Dermatology 1996; **37(2)**: 102-113.
7. Pannu K, Singh BD. Ectodermal dyasplasia with total anodontia: Rehabilitation of a seven year old child. J Indian Soc Pedo Prev Dent 2002; **20(3)**:114-117
8. Shigli A, Reedy RV, Hugar SM, Deshpande D. Hypohidrotic ectodermal dysplasia: a unique approach to esthetic and prosthetic management: A case report. J Indian Soc Pedo Prev Dent 2005; **23(1)**:31-34.
9. Vieira KA, Teixeiva MS, Guirado CG, Cariaro MB. Prosthodontic treatment of with complete anodontia: case report. Quintessence Int 2007; **38**:75-80.
10. Thurnam J. Two cases in which skin hair and teeth were imperfectly developed. Procedings of the royal Medical and chirurgical Society 1848; **71**:71-81.
11. Adolfo Pipa Vallejo, Elena Lopez-Arranz Monje, Manuel Gonzalez Garcia, Miguel Martinez Fernandez, Fernando Blanco-MorenoAlvarez-Bullya. Treatment with removable prosthesis in hypohidrotic ectodermal dysplasia. A clinical case. Med Oral Patol Oral Cir Bucal 2008 ; **13(2)**:E119-123.
12. Sweeney IP, Ferruson JW, Heggic AA, Lucasto. Treatment outcomes for adolescent ectodermal dysplasia patients treated with dental implants. Int J Paediatr Dent 2005;**15(4)**:241-248.
13. Penarrocha M, Sanchis JM, Frutos JR, Estrela F, PCJ. Oral rehabilitation with implants in a child with hypohidrotic ectodermal dysplasia. Med Oral 2000; **5(4)**:283-286.
14. Alcan T, Basa S, Kargcul B Growth analysis of a patient with ectodermal dysplasia treated with endosseous implants. 6 year follow up. J Oral rehabil 2006; **33(3)**: 175 – 182.
15. Suris, carnichael RP, Tompson BD. simultaneous functional and fixed appliance therapy for growth modification and dental alignment prior to prosthetic rehabilitation in hypohidrotic ectodermal dysplasia; a clinical report. J prosthet Dent 2004; **92(5)**: 428-433
16. Guler M; cildvi S, Iseri V, sandalli N, Dilek O, Hypohidrotic ectodermal dysplasia with bilateral impacted teeth at the coronoid process a case rehabilitated with mini dental implants. Oral Surgery Oral Medicine Oral Pathology Oral Radiology Endodontics 2005; **99(5)**: 34-38.
17. Till and Marques AP Ectodermal dysplasia Treatment considerations and case reports. North West Dent. 1992; **71**: 25-28.
18. Franchi L, Branchi R, Tollaro I. Craniofacial changes following early prosthetic treatment in a case of Hypohidrotic ectodermal dysplasia with complete anodontia. J Dent Child 1998; **65**:116-121.