

CASE REPORT

Secondary Correction Of Orbital Deformity Using Iliac Crest Bone Graft

Gautam Dendukuri¹, Mohan AP², Sukhvinder Bindra³

Department of Oral and Maxillofacial Surgery
Kamineni Institute of Dental Sciences,
Marketpally

Professor¹
Professor²
Assistant Professor³

Article Info

Received: 18th October, 2009

Review Completed: 17th November, 2009

Accepted: 10th December, 2009

Available Online: 18th April, 2010

© NAD, 2010 - All rights reserved

Abstract :

Blowout fractures can cause numerous problems, including unfavorable esthetics, diplopia, ocular muscle entrapment, and enophthalmos. Diplopia and enophthalmos are relatively common problems associated with this fracture, as is herniation of the orbital contents with defects of the orbital floor. To manage these problems, orbital floor reconstruction is necessary. The aim of the surgery is to avert anatomic and functional defects. Various materials have been used for orbital reconstruction. Here by presenting a case of 33 year old male in whom secondary correction of enophthalmos has been done using iliac crest graft material for orbital floor reconstruction.

Key words: *Blowout fracture, Enophthalmos, Iliac Crest Bone Graft*

INTRODUCTION

Orbital fracture patterns vary considerably in their location as well as in their degree of severity.¹ Multiple portions of the orbit can be fractured and several internal orbital walls therefore injured simultaneously. Blow out fractures of the orbit most commonly involve the floor and or medial wall.²

Significant complications can occur as a result of these injuries, including enophthalmos, diplopia, and restriction of gaze.³ In general, the volume of the orbit will change relative to the displacement of one or more walls. If the volume of the orbit is increased relative to the volume of the intraorbital tissue content, the globe will sink inward (enophthalmos) and possibly downwards (hypophthalmos). From a functional stand point, displacement of a bony wall disturbs the position of the soft tissue, causing problems of eye movement and diplopia.² Additionally direct damage to the soft tissues of the orbit can lead to scar contracture, globe dystopia, and dysmotility, loss of vision if globe is injured.

Orbital wall fracture is a defect fracture where bone fragments with torn periosteum are pushed outside of the original bony orbit. There is no intact bone even near the defect area except the thin rim surrounding the defect fracture. The purpose of the defect repair is to support orbital contents, free entrapped tissue, and especially, restore the original orbital volume.⁴

Many implant materials are available for orbital reconstruction and are grossly classified as autologous, allogenic, and alloplastic.⁵ The treatment of choice to restore absent bone segments is to replace the defect with autogenous bone. Autologous materials are generally biodegradable and include septal cartilage, ear cartilage, bone from calvaria, the anterior and lateral maxillary antral wall, mandibular symphysis, mandibular coronoid process, rib, and iliac crest.⁶

In the present case, iliac crest has been used for orbital floor reconstruction in a patient having post traumatic enophthalmos.

Address for correspondence:
gautamden@hotmail.com

CASE REPORT

A 33 year old male patient presented to our department with chief complaint of double vision while looking upwards and his eyes not being at the same level since one and a half year. Past history revealed that patient met with a road traffic accident and sustained facial injuries one and a half year ago. There was history of loss of consciousness for about 10-15 minutes but no history of vomiting. He was diagnosed having right frontal bone, orbital blow out and zygomaticomaxillary complex fracture. Patient was treated conservatively for head injury at that time but gradually patient started having double vision and one year ago he underwent surgery for right orbital floor fracture in which orbital floor augmentation was done using silastic implants.

On Extra oral examination, Patient was having significant enophthalmos of the right eye (Fig 1), diplopia on upward gaze and dystopia (change in ocular level). Intraorally, occlusion was normal and there was no other significant finding. Three dimensional computed tomography showed malunited right frontal bone, orbital blow out and zygomaticomaxillary complex fracture(Fig 2). There was radiopacity in right maxillary sinus suggesting herniation of orbital contents into the sinus.

Patient was medically fit and was planned for orbital floor augmentation with iliac crest under general anesthesia.

SURGICAL PROCEDURE

Transconjunctival incision (Fig 3) was used to approach orbital floor. Local anesthesia Xylocaine with adrenaline 1: 80,000 was injected under the conjunctiva to aid in hemostasis. Two or three traction sutures were placed through the lower lid to assist in subsequent surgery. After stabilizing the lower eyelid a small incision was made (3mm) long below the tarsal plate on the medial aspect and in the line with punctum. Fine scissors were introduced to dissect the conjunctiva and orbital septum from the orbicularis oculi muscle. Preseptal approach was used to keep orbital content out of the surgical field. After that orbital contents and lower eyelid were retracted to place an incision in the lower lid periosteum. Periosteum was lifted to expose the orbital floor. The entrapped tissues were released and

3 silastic implants (Fig 4) were removed. A defect of 2.5X3.0mm was seen.

To harvest iliac crest graft medial approach was used and a monocortical graft of 3X4 cm (Fig 5) was harvested which was shaped to fill the defect completely. Wound was closed in layers and a drain was kept in place.

The graft was secured in the orbital floor with cortical side toward the globe but was not fixed to the adjacent bone. Only one 5-0 vicryl suture was placed for transconjunctival incision.

DISCUSSION

Following orbital fracture, secondary problems result in spite of proper treatment. Apart from scarring resulting from the direct injury or the operative approach, there can be volume changes and soft tissue deformity due to incomplete correction or failure to correct bony displacement. In our patient also although the silastic implants were placed but still patient developed enophthalmos.

In correcting the enophthalmos, the goals are to return the intraorbital tissues to their normal position, to seal the defects, and to restore volume if there is expansion of the walls. As in primary management of blow-out fractures, a complete exploration of the posterior orbital floor is essential. Based upon the CT findings, volume addition should be performed wherever the bony displacement has occurred. Slight overcorrection is preferred as compared to the other side to compensate for resorption of the graft later. Fortunately, in our patient there was no residual entrapment of the inferior rectus muscle and this was confirmed by forced-duction test.

Many surgical approaches to orbital fractures have been promulgated, with most involving the orbital floor. Floor fractures can be approached through a transconjunctival incision (inferior fornix) with a lateral canthotomy extension for wider exposure, an infraciliary skin/muscle blepharoplasty route, or a skin incision directly over the inferior orbital rim. The transconjunctival approach first appeared in the literature in the early 1900s as a cosmetic procedure for the treatment of fat herniation in the lower eyelids.⁷ Later this approach was developed by Converse et al (1973)⁸ and Tesier (1973)⁹ for the treatment of fractures. This approach

has following advantages: lower incidence of ectropion,¹⁰ no visible external scar and it facilitates the disengagement of any entrapped or prolapsed orbital tissues under direct vision.

The aim of orbital surgery is to restore the orbit to the pre-morbid and aesthetic form with preservation of function. The functions of an orbital implant are – to seal off the antral cavity from the orbit, to provide a physiologically acceptable and physically inert smooth surface, which will not form adhesions to restore the contour and dimensions of the orbit and to provide some indirect support for the globe.

Autogenous tissues were the first material used to reconstruct the internal orbit¹¹ and has been the gold standard to provide framework for facial skeleton and orbital walls.¹² Autogenous bone ensures the re-establishment of bony continuity across the defects and it becomes incorporated into the host as new bone, larger volumes of graft material necessary for complex reconstructions are likely to be better tolerated than equal volumes of alloplastic materials. The other advantages of autogenous bone are its relative resistance to infection, lack of host response against the graft and lack of concern for late extrusion.³ Donor site morbidity, variable graft resorption, and limited ability to contour some types of the bone top the list of disadvantages.³

Endochondral and membranous bone source are used in orbital reconstruction with the major donor sites for each being iliac crest and calvarium³. Iliac crest was preferred since transconjunctival incision was planned and patient was also comfortable with it. Iliac crest graft provides larger volume and bone can be harvested simultaneously to orbital exploration. Both de Visscher and van der Wal¹³, and Bartkowski and Krzystkova¹⁴ used iliac crest graft for orbital floor or medial wall reconstruction and found that it was extremely well tolerated and is adequate material for orbital floor reconstruction. Sullivan and his co-workers¹⁵ also concluded in their study that the medial cortex of anterior iliac crest is moldable and after trimming is easily adapted to the shape and form of the internal orbital wall.

Patient recovered well (Fig 6) without any complications. Follow up till 6 months have been done and will continue for the next 2 years.

CONCLUSION

Iliac crest graft in secondary reconstruction of orbital floor in management of enophthalmos has been found better than sialistic implant in the present case as it provides good volume to fill the defect.

REFERENCES

1. Manolidis S Weeks BH, Kirby M, et al. Classifications and surgical management of orbital fractures: experience with 111 orbital reconstructions. *J Craniofac Surg* 2002; **13**:726-737.
2. Siddique S A, Mathog RH. A Comparison of Parietal and Iliac Crest Bone Grafts for Orbital Reconstruction. *J Oral Maxillofac Surg* 2002; **60**:44-50.
3. Potter JK, Ellis E III. Biomaterials for reconstruction of the Internal Orbit. *J Oral Maxillofac Surg* 2002; **60**:1280-1297.
4. Kontio R. Treatment of orbital fractures: The case for reconstruction with autogenous bone. *J Oral Maxillofac Surg* 2004; **62**:863-868.
5. Sakakibara S, Hashikawa K, Terashi H, Tahara S. Reconstruction of the Orbital Floor With Sheets of Autogenous Iliac Cancellous Bone. *J Oral Maxillofac Surg* 2009; **67**:957-961.
6. Enislidis G. Treatment of orbital fractures: The case for treatment with resorbable materials. *J Oral Maxillofac Surg* 2004; **62**: 869-872.
7. Bourguet J. Notre traitement chirurgical de 'poches sous les yeux' sans cicatrice. *Archives Frano-Belges de chirurgie* 1928; **31**: 133.
8. Converse JM, Firmin F, Wood-Smith, D and Friedland, JA. The conjunctival approach in orbital fractures. *Plast Reconstr Surg* 1973; **52**: 656-657.
9. Tessier P. The conjunctival approach to the orbital floor and maxillofacial in congenital malformation and trauma. *J Maxillofac Surgery* 1973; **1**: 3-8.
10. Boush GA, Lemke BN. Progressive infraorbital nerve hypesthesia as a primary indication for blowout fracture repair. *Ophthalm Plast Reconstr Surg* 1994; **10**: 271-275.
11. Converse JM, Smith B, Obear MF et al. Orbital blow out fractures: A ten year survey. *Plast Reconstr Surg* 1967; **39**:20-36.
12. Ellis E III, Tan Y. Assessment of internal orbital reconstruction for pure blow out fractures: Cranial bone versus titanium mesh. *J Oral Maxillofac Surg* 2003; **61**: 442-453.
13. de Visscher JG, van der Wal KG. Medial orbital wall fracture with enophthalmos. *J Craniomaxillofac Surg* 1988; **16**:55.
14. Bartkowski SB, Krzystkova KM. Blow out fracture of the orbit. Diagnostic and therapeutic considerations, and results in 90 patients treated *J Maxillofac Surgery* 1982; **10**:155-164.
15. Sullivan PK, Rosenstein DA, Holmes RE et al. Bone graft reconstruction of the monkey orbital floor with iliac grafts and titanium mesh plates; A histometric study. *Plast Reconstr Surg* 1993; **91**:769-775.



Fig 1 Pre operative photo showing enophthalmos of right eye

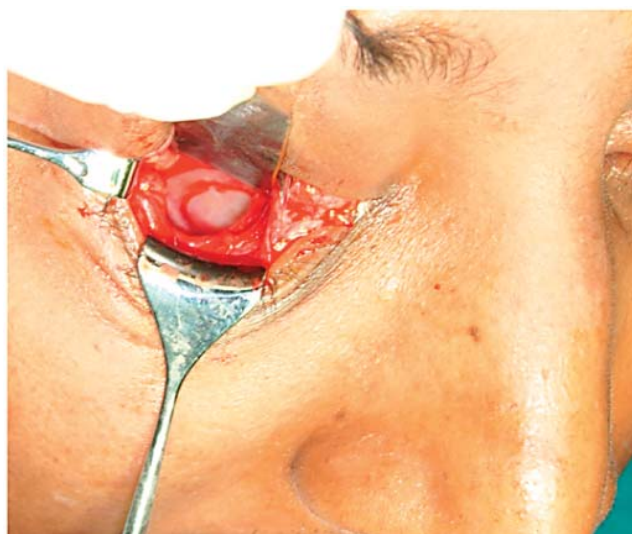

Fig 4 Silastic implant

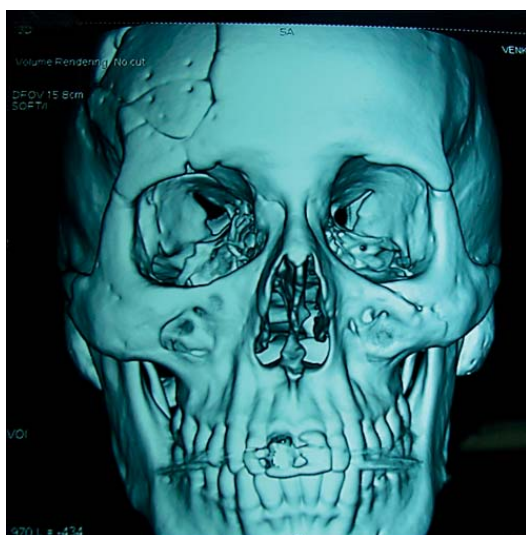

Fig 2 Three dimensional CT scan showing increased right orbital volume

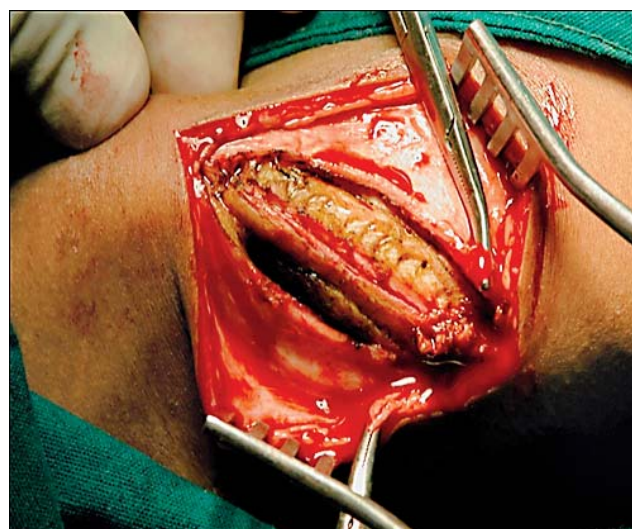


Fig 5 Harvesting iliac crest graft

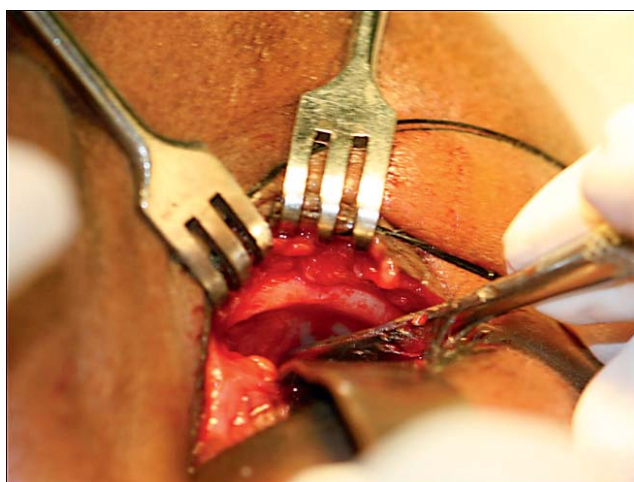


Fig 3 Transconjunctival incision

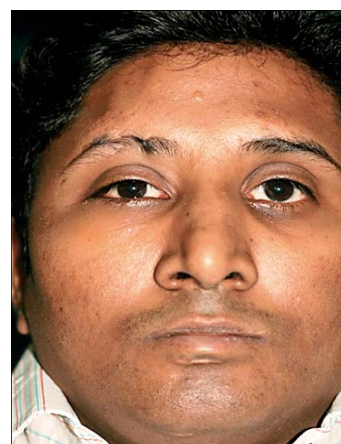

Fig 6 Post operative