INDIAN JOURNAL OF DENTAL ADVANCEMENTS

Journal homepage: www.nacd.in

ORIGINAL RESEARCH

Relationship of duration of oral contraceptive therapy on human periodontium - A clinical, radiological and biochemical study

Geetha Vijay

Department of periodontics,
Vydehi Institute of Dental Sciences
 # 82 EPIP Area, Whitefield,
Bangalore-560 066

Professor& Head

ABSTRACT:

Background: Many investigators have postulated that sex hormones modify the response of gingival to local irritation thereby causing histological and histochemical changes in the gingiva. Few studies have also noticed changes in the alveolar bone. There is hardly any study in India to focus a comprehensive clinico-pathological study on the users of oral contraceptives for different durations regarding their oral health status.

Methods: A clinical, radiological and biochemical (serum calcium, phosphorous and alkaline phosphatase) study was undertaken to evaluate comparatively the effect of different durations of oral contraceptive therapy on the periodontium of 43 women. In the control group, 22 individuals, who have never used hormonal contraceptives or any other steroids, were included.

Results: The quantity of plaque and status of periodontal disease was higher in patients on oral contraceptives than in control group. Intra oral radiographs showed changes in the alveolar bone like trabecular condensation, radiopacities and thickening of lamina dura in patients on oral contraceptives.

Conclusion: Oral contraceptive therapy especially of longer duration could lead to poorer oral hygiene status, increased susceptibility to periodontal disease and radiographic changes of the alveolar bone like lamina dura thickening, trabecular condensation and radio opacities. There was a trend for decreased serum calcium and phosphorus levels and an increased alkaline phosphatase level associated with longer duration of oral contraceptive use.

Key words: ***Alveolar bone, Estrogen, Lamina dura, Oral contraceptives, Periodontium.***

Article Info
Received: February 18, 2010
Review Completed: March 10, 2010
Accepted: March 25, 2010
Available Online: August, 2010
© **NAD, 2010** - All rights reserved

Introduction

The rapid advances in medical sciences and the increasing number of patients taking one or more drugs have increased the importance of physical evaluation as a factor in providing comprehensive dental care. Several drugs including sex steroids used for contraception have untoward effect on other structures of the human body[1] and also influence the course of periodontal disease[2].

Email for correspondence:
drvijayr53@yahoo.com, drgeethavijay@hotmail.com

Many investigators have postulated that sex hormones modify the response of gingiva to local irritation thereby causing histological and histochemical changes in the gingiva. Few studies have also noticed changes in the alveolar bone[3,4].

Although extensive work has been carried out in this field particularly changes in the gingiva in contradistinction very less work has been done to assess the changes in the periodontal tissues (particularly alveolar bone) and associated blood serum changes as related to duration of

contraceptive therapy. Of the studies conducted in man, it shows that there is dearth of well planned survey to evaluate the effect of these drugs on the periodontium.

There has yet to be a study which could assess the alterations in the pattern of alveolar bone, the biochemistry of serum calcium, phosphorus and alkaline phosphatase. Hence the present study has been prompted to be undertaken which can help us to gain an insight for correlating the clinical changes in the periodontal tissues, with radiographic changes in the alveolar bone and associated changes in the blood serum in individuals on long term oral contraceptive therapy.

Material and methods

A clinical, radiological and biochemical (serum calcium, phosphorous and alkaline phosphatase) study was undertaken to evaluate comparatively the effect of different durations of oral contraceptive therapy on the periodontium. The participants for the present study included 65 females between the ages of 20 to 35 years, who were attending the Family welfare department of Kasturba medical college, Manipal and also from the Family welfare centre, Udupi. The participants were placed in 2 groups, experimental and control. 43 women, who were on oral contraceptives for variable periods were included in the experimental. 22 women, who have either never used hormonal contraceptives or any other steroids or were not pregnant, formed the control group. The experimental group was further subdivided into 3 groups according to the duration of contraceptive therapy.

Group I consisted of 18 subjects who were on oral contraceptive therapy for 6 months to 1.5 years, group II had 21 subjects who were on therapy for more than 1.5 years to less than 5years and group III consisted of 4 subjects who were on oral contraceptives for more than 5yerars. The medication taken by the subjects in the experimental group were of the combined estrogen and progesterone type.

The subjects were clinically examined intra orally with the help of mouth mirror and probe under artificial light. Two tone disclosing solution was applied and the state of oral hygiene was graded according to the plaque index system of Silness and Loe. Each of the 4 areas of all the teeth examined represents the plaque index score for the particular case. The gingiva was dried with a blast of air and the color, consistency, contour, texture and a tendency for bleeding was noted.

The periodontal index (PI) was intended to estimate deeper periodontal disease by measuring the presence or absence of gingival inflammation, pocket formation and loss of maticatory function. PI score per individual was determined by summing all of the tooth scores and dividing by the number of the teeth examined.

Full mouth periapical radiographs, using short cone bisecting angle technique with 55kvp, 7mA Philips Oralix machine and Kodak Ekta speed films, was taken for all the subjects included in the study. The radiographs were studied simultaneously by 2 dental radiologists for the presence of thickening of lamina dura, trabecular condensation and presence of radiopaque masses or areas.

All the participants were subjected to blood examination for biochemical assessment of serum calcium, phosphorus and alkaline phosphatase by collecting 5cc of blood from cubital vein.

Where parametric statistics (mean standard deviation) were available, the difference between mean was compared using student's't' test. In case of frequency distribution chi-square test was used.

Permission was obtained from the institution and informed consent from all the individuals who participated in this study.

Results

A total of 65 women were considered for the present study; 43 of them, who were under oral contraceptives for variable period were included in the experimental group (I,II, and III), while 22 who were either not on oral contraceptives (or any steroids) or were pregnant formed the control group. Subjects (18) in Group I had a mean age of 26.94 years with a S.D of ± 3.28, while for Group II (21) the mean age was 29.05 with S.D of ±2.04 and for Group III (4) the mean age was 30.75 with a S.D of 2.06. For the control group (22) the mean age was 25.09 with a S.D of 3.10 (table1).

Oral hygiene status of all groups (table 2) was assessed by Loe and Silness plaque Index. The control group showed a mean plaque index of 1.0725 ± 0.5168, while Group I, II, and III showed mean plaque index of 2.123 ± 0.3967, 2.892 ± 0.3550, and 3.115 ± 0.1816 respectively. The student't' test for a independent sample was done to find the significance of difference of means among the control and various experimental groups. In all the 3 groups the difference among mean were significant at 0.1% level, thus showing a worsening of oral hygiene status with oral contraceptive therapy.

Table 3 shows the periodontal hygiene status of participants on oral contraceptives. The periodontal index was highest for Group III (1.280 ±0.4387). For Group I & II and control the periodontal index was 0.771 ± 0.1635, 0.771 ± 0.1373, and 0.410 ± 0.1635 respectively. The difference between means for experimental group and controls was significant at 0.01 levels.

There was a statistical significance between OHI & PI between Group I & II (t value = 6.3455, p =0.001) and Group I & III (t = 4.3460, p = 0.001). But these indices were not significantly different between Group II & III thereby suggesting that after a certain period of duration of oral contraceptive therapy, the effects are similar.

Three types of radiographic changes were observed in the present study; lamina dura thickening (fig.1), trabecular condensation (fig.2), and radiopaque mass (fig.3). Radiographic changes were considered to be present if any one of the above changes were seen and absent when none of them were present (table 4). In the control group, radiographic changes were present in 22.7% of the participants while radiographic changes were observed in 33.3%, 85%, and 75% of participants in Group I, II, and III. This distribution was statistically analyzed. Group II & III was combined and it was found that x^2 value = 17.5384, was very highly significant p=0.001. Histogram shows the frequency of various radiographic changes in different groups.

Serum calcium and phosphorus were estimated and the results are shown in table 5. The values for calcium and phosphorous were within normal range but there was a tendency to decrease in groups with a longer duration of oral contraceptive therapy. The controls had serum calcium of 10.16 mg ± 0.3788 and phosphorous 3.84 ± 0.5019. For Group I the Calcium & phosphorous values were 10.12 mg. ± 0.4519 and 3.78 ±.5216; 9.66 ± 0.4566 and 3.14 ±.5510 for Group II; 9.6 ± 0.432 and 3.2 ±.6325 for Group III. Student't' test done on these values showed that there was a significant difference in the means between control and Group II for serum calcium and phosphorus and for Group I versus Group II for both the minerals. Serum alkaline phosphatase was determined only in patients on oral contraceptives. It was found that in Group I, the value for alkaline phosphatase was 7.5 ± 1.9340 and Group III 11.25 ± 1.7078.

DISCUSSION

The aim of this study was to investigate the inter relationship between the responses of periodontal tissues (gingiva & alveolar bone) and any changes in blood chemistry of subjects who had been taking oral contraceptives for various periods of time compared with the controls.

The perusal of results showed that the oral hygiene status using the plaque index (Silness and Loe) had a progressive deterioration with the prolonged use of oral contraceptives. In all experimental groups the plaque indices were greater than the control and the highest value was for Group III with the maximum exposure to the drug. Lindhe and Bjorn[5] found no difference between controls and patients on oral contraceptives. Knight and Wade[6] similarly reported no change in plaque accumulation after a short term of oral contraceptive use and after duration of more than 1.5 years of oral contraceptive use, the plaque score was lowered in his series of patients. Agreeing with the results of the present study were studies by Das et al[7,8] and Maria Korandy et al[9]. In the other Indian study available, Das et al[7] found in their patients under oral contraceptives to have poorer oral hygiene than patients not taking any oral contraceptives. Kenneth and Kwalkwarff[10] had assessed the effect of accumulated dose of oral contraceptives and found that increased accumulative dose of oral contraceptive had no effect on oral debris index, though there was an increase in

gingival index. The plaque index used in my study was more sensitive than the debris index used by Kenneth and Kalwarf.

The periodontal health of subjects on oral contraceptives was worse compared to the controls and they also show deterioration of the condition (as evidenced by larger periodontal index score) with longer duration of drug intake. Most of the workers had used gingival indices to measure the effect of the drug. Lindhe and Bjorn[5] reported an increased gingival exudates measurement; Knight and Wade[6] reported no gingival changes after short term therapy (< 1.5 years) but after 1.5 years of intake, the gingival index was higher with more loss of periodontal attachment. There were 3 studies which used periodontal indices comparable to our study (Das et al[7, 8], Maria Korandy et al,[9] and Knight and Wade[6]). They all reported increased periodontal index score after oral contraceptive therapy as in my study. Das et al[8] reported that though periodontal index was increased, there was no correlation to pocket depth.

Pregnancy tumor like hyperplastic changes were reported in patients on oral contraceptives by Pearlman.[11] In my study, though there was no tumor like growth, hyperplastic gingivitis was observed in one case.

The adverse effects of oral steroid therapy on gingival and periodontal health have been explained on the basis of many mechanisms such as microvascular topography and permeability of gingival tissues,[12, 13] vascular proliferation[14], increase in the number of polymorpho nuclear leucocytes within the gingival sulcus[15], and in combination with estradiol increased synthesis of prostaglandin E_2 in gingival tissues[16] and the presence of specific receptors for progesterone and estrogen in the periodontium.[17] Thus by any or all of these mechanisms, sex steroids might significantly affect the periodontium.

Loss of lamina dura is seen in menopausal women which is a period of estrogen deficiency. Therefore we might postulate that a large amount of estrogen could lead to a lamina dura integrity and thickening.

The present study was in accordance with the study of Darzenta[3] who also reported that out of their 204 patient samples (112 women and 92 men) positive radiographic findings were more frequent in women and amongst them there was a statistical increase in women using oral contraceptives. In view of Darzenta,[3] the opacities were thought to be due to thickening of endosteal plates of bone as a result of the estrogenic effect.

Radiographic changes were explained at the systemic and local level according to various studies.[18] At the systemic level, it was suggested that if estrogens play a role in modulating the parathyroid on bone the effect was one of bone apposition which could account for a denser and more radiopaque endosteum. Experimental studies done by Bernick et al[19] even suggested that the mode of action of estrogen might be at a local level. The changes produced might be due to the influence of estrogen on the components of the connective tissue. Whether the action in producing radiographic changes are at systemic or local level, dental radiographs may serve to indicate the use of oral contraceptives for longer periods either in past or present.

The serum calcium and phosphorus values in individuals taking oral contraceptives were within normal limits, but were towards smaller value. The results of the present study are in agreement with the study done by Goldsmith et al.[20] According to their study in the steady state (control) bone formation and resorption were equal, the amount of mineral deposited is equivalent to the amount of mineral released, and the serum and urinary levels of the components of bone mineral reflected this balance. However when bone formation exceeds bone resorption, as in women on oral contraceptives[21] more mineral is deposited than is released into the circulation. Thus the concentrations in serum were lowered. Serum alkaline phosphatase increased with the duration of therapy, though still within normal limits. The increase in alkaline phosphatase levels is in agreement with the findings of previous workers.[22] The increase in alkaline phosphatase can be explained on the basis of effects of oral contraceptives on liver.

ACKNOWLEDGEMENT

I wish to sincerely thank Prof. T.R.Gururaja Rao and Prof.M.S.Narayana Rao for their able guidance in completing this study.

REFERENCES

1. Jeffcoat N. Principles of Gynecology. 4th edn. Edinburgh: T.A.Constable Ltd, 1975
2. Newman MG, Takei HH, Klokkevold PR, Carranza FA. Carranza's clinical periodontology. 10th edn. Elsevier: New Delhi, 2007:622
3. Nicolas, Darzenta C, Guinta JL. Radiographic changes of the mandible related to oral contraceptives. J.oral.surg 1977; **3**:478-481
4. Nutlay AG, Bhasker SN, Weinnman JJ, Budy AB. Effect of estrogen on the gingiva and alveolar bone of molars in rats and mice. J.Dent.Res 1954; **33**:115-127
5. Lindhe J and Bjorn AL. Influence of hormonal contraceptives on the gingiva of women. J.Periodont.Res 1974; 2
6. Knight GM, Wade AB. The effects of hormonal contraceptives on the human periodontium. J.Periodont.Res 1974; **9**:18-22
7. Das AK, Bhowmick S, Dutta A. Oral contraceptives and periodontal diseases I. JIDA 1971; 43:47
8. Das AK, Bhowmick S, Dutta A. Oral contraceptives and periodontal diseases II. JIDA 1971; **43**:155
9. Korandy M, Zakely Z, Lajos. Supplement. Dental abstract 1976; 428-429
10. Kalkwarf KL. Effect of oral contraceptive therapy on gingival inflammation in humans. J.Periodont. 1978; **49**:560-563
11. Pearlman BA. An oral contraceptive drug and gingival enlargement: The relationship between local and systemic factors. J.Clinical Periodontology 1974; **1**:47-51
12. Lindhe J, Branemark PK. Changes in microcirculation after local application of sex hormones. J.Periodont.Res. 1967; **2**:185
13. Lindhe J, Branemark PK. Changes in vascular permeability after local application of sex hormones. J.Periodont.Res. 1967; **2**:259
14. Lindhe J, Berch J, Branemark PK. Vascular proliferation in pseudo pregnant rabbits. J.Periodont.Res. 1968; **3**:12
15. Hugoson A. gingival inflammation and female sex hormones.J.Periodont.Res (supplement) 1970; **5**:1
16. El-Attar. Prostaglandin E_2 in human gingiva in health and disease and its stimulation by female sex hormones, prostaglandins. 1976; **11**:331
17. Thomas, Aufdemorte B, Sheridan PJ. Nuclear uptake of sex steroids in gingiva of the babbon. J.Periodont. 1981; **52**:430
18. Robin PS, Howard JE. Histchemical study on the role of acid mucopolysaccharides in calcificability and calcification. Trans. Mary conference on metabolic interrelations. 1950; **2**:155-166.
19. Bernick S, Ershoff BH. Histochemical study of bone in estrogen treated rats. J.Dent.Res. 1963; 42
20. Goldsmith J, Jhonston M. Bone mineral: effect of oral contraceptives, pregnancy, and lactation. J.Bone and Joint Surgery. 1975; 57
21. Aitken JM, Collen MF, Lindsay R, Hart DM. estrogen replacement therapy for prevention of osteoparosis after oophorectomy. Brit.Med.J. 1973; **3**:515-18
22. Kay HD. Plasma phosphatase H: The enzyme in disease, particularly in bone disease. J.Biol.Chem. 1930; **89**:249

Table 1

Group	Number	AgeMean	(years)SD
Control	22	25.09	3.10
Group I	18	26.94	3.28
Group II	21	29.05	2.04
Group III	4	30.75	2.06
Total	65	-	-

Distribution of sample

Table 2

Group	No.	Mean ±	SD	't' value	'P'
Control	22	1.725	0.5168	-	-
Group I	18	2.123	0.3967	6.7197	0.001
Group II	21	2.892	0.3550	12.6541	0.001
Group III	4	3.115	0.1816	7.3255	0.001

Oral hygiene status in control and experimental group (Plaque index by Silness and Loe)

Table 3

Group	No.	PI Index Mean ±	S.D	't' value	'P' value
Control 22	0.410	0.1685	-	-	
Group I 18	0.771	0.1373	7.4413	< 0.001	
Group II 21	1.041	0.3798	7.1380	< 0.001	
Group III 4	1	280	0.4387	7.3542	< 0.001

Periodontal health status in control and experimental group (Periodontal index by Russel)

Table 4

Group	Radiographic changes Present	Radiographic changes Absent	Total No. of patients
Control	5 (22.7%)	17 (77.2%)	22
Group I	6 (33.3%)	12 (66.6%)	18
Group II	18 (85.71%)	3 (14.2%)	21
Group III	3 (75%)	1(20%)	4

Radiographic changes in control and experimental groups

Table 5

	Calcium		Phosphorous		Alkaline Phosphatase	
	Mean	SD	Mean	SD	Mean	SD
Control	10.16	0.3788	3.8	.5019	-	-
Group I	10.12	0.4519	3,78	.5216	7.5	2.3825
Group II	9.66	0.4566	3.14	.5510	9.48	1.9340
Group III	9.6	0.432	3.2	.6325	11.25	1.7078

Estimation of calcium, phosphorus, and alkaline phosphatase in serum of control and experimental groups

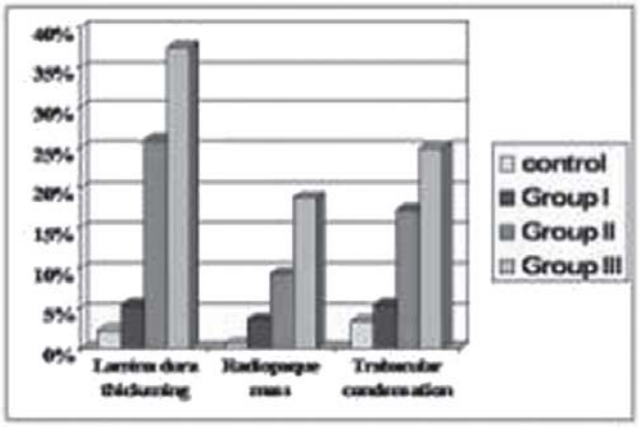

Histogram shows the frequency of various radiographic changes in different groups.

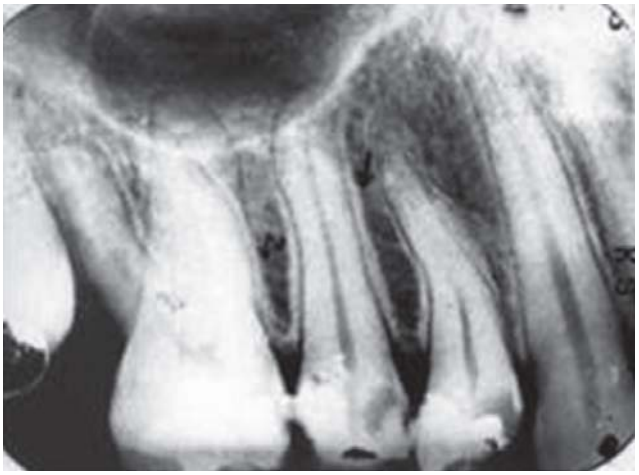

Figure 1: IOPA radiograph showing thickening of lamina dura

Figure 2: IOPA radiograph showing trabecular condensation

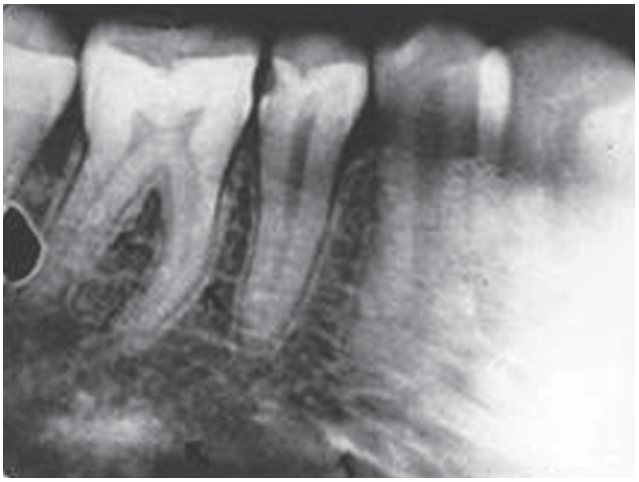

Figure 3: IOPA radiograph showing radiopaque mass.