INDIAN JOURNAL OF DENTAL ADVANCEMENTS

Journal homepage: www.nacd.in

CASE REPORT

Palatogingival Grooves

Shankar Ram[1], Uma Sudhakar[2], Pramod V[3], Radhika A[4]

Dept. Of Periodontics
Thai Moogambigai Dental College
Mugappair, Chennai-107, India

Sr. Lecturer[1]
Professor[2]
PG Student[3 & 4]

Article Info
Received: February 9, 2010
Review Completed: February 17, 2010
Accepted: February 28, 2010
Available Online: August, 2010

ABSTRACT:

Palatogingival grooves a developmental anamoly, initiate on the enamel and can extend a significant distance on the root surface, providing a plaque retentive area that is difficult to instrument. The diagnosis of these grooves is quite difficult, as they cannot be differentiated in the X-ray images. Specialized diagnostic techniques like 3D computed tomography had been used for detecting the apico-coronal and bucco-lingual extent of these grooves.The treatment procedures employed for treating palatogingival grooves will include pulpectomy if the tooth is nonvital along with odontoplasty of the groove or restoration of the groove with GIC after the elevation of mucoperiosteal flap. Bone defects around the involved teeth also has to be treated with grafts and membrane.This case report describes the diagnosis and treatment of a palatogingival groove on maxillary lateral incisors.

Key words: ***Palatogingival groove, CT scan, Bone grafts, Guided tissue regeneration***

Introduction

Periodontitis is defined as the inflammatory disease of tooth supporting structures caused by microorganisms or by group of specific microorganisms resulting in progressive destruction of the periodontal ligament and alveolar bone with pocket formation or recession or both[1]. Clinically gingivitis and periodontitis are differentiated with the presence of attachment loss, which is seen in the former. Periodontitis is accompanied by periodontal pocket formation which is a result of apical migration of junctional epithelium along with significant changes in the levels and density of alveolar bone.

According to the American Academy of Periodontology (AAP) International workshop for classification held during the year 1999, the developmental and acquired deformities and conditions, were grouped together as an entity that could lead to periodontal destruction[1]. Developmental and acquired deformities are those conditions and structural changes to the tooth and or soft tissue that could bear a significant threat to the Periodontium and lead to definitive attachment loss.

These developmental and acquired deformities are sub-classified into the following:

1. Localized tooth related factors that predispose to plaque induced gingivitis or periodontitis.

1.1. Tooth anatomic factors

1.2. Dental Restorations or appliances

1.3. Root fractures

1.4. Cervical root resorption and cemental tears.

Email for correspondence:
shankarram_2005@yahoo.com

2. Mucogingival deformities and conditions around teeth.
3. Mucogingival deformities and conditions on edentulous ridges.
4. Occlusal trauma.

The tooth anatomic factors are malformation of tooth during their developmental phase or improper positioning of the teeth in the arch. The cervical enamel projections and enamel pearls are one such anatomic variations that can to plaque accumulation and periodontal destruction. They tend to cause more destruction when present in furcation areas like mandibular molars where the incidence of finding them is 15 - 25% and in maxillary molars where their incidence is 9 - 25%. Proximal root grooves on incisors and maxillary premolars, tooth location and malalignment can predispose to poor oral hygiene and eventual alveolar bone loss leading to attachment loss. Open contacts between teeth can also cause attachment loss because of food impaction. Palatogingival grooves are also one such developmental anomaly that are found primarily on maxillary incisors and can lead to alveolar bone loss, clinical attachment loss and pocket formation.

Palatogingival groove or Radicular Lingual Groove (RLG) is a developmental anomaly in which an infolding of the inner enamel epithelium and Hertwig's epithelial root sheath create a groove that passes from the cingulum of maxillary incisors apically onto the root. Radicular lingual grooves can create periodontal and pulpal pathology. This groove creates an area where plaque accumulation can be difficult if not impossible to control using oral hygiene measures. Withers et al[2] in 1981 observed that palatogingival grooves are found on 2.3% of maxillary incisors (4.4% maxillary laterals and 0.28% of maxillary centrals) Everett[1] in 1972 observed that palatogingival grooves found on 2.8% of lateral incisors. While Kogon[1] in 1986 Examined 3168 extracted maxillary central and lateral incisors. Palatogingival grooves found on 4.6% of maxillary incisors (3.4% maxillary centrals and 5.6% on maxillary lateral incisors) 54% of palatogingival grooves terminated on the root with 43% of those extending less than 5mm and 47% extending 6-10mm.

Case report

A male patient aged 24 years reported to the Dept. of Periodontology, Thai Moogambigai Dental College and Hospital Chennai with chief complaint of sensitivity and spacing concerning upper anteriors. The history of chief complaint revealed that the sensitivity was mainly during consuming cold food which started for the past 6 months and gradually increased. Pathologic tooth migration which caused increase in spacing between upper anteriors was noticed by the patient for the past 2 months.

On extra-oral examination there were no palpable lymph nodes, face was bilaterally symmetrical and lips were competent. On intra-oral examination gingival color was reddish, gingival contour showed rolled out marginal gingiva and interdental papillae was flattened, consistency was soft and edematous and surface texture was smooth because of loss of stippling in the upper anterior region. Oral hygiene index was used to measure debris and calculus which was 1.5 and the inference being poor oral hygiene. There was no mobility observed with the teeth and the patient had not got his teeth extracted or lost.

Fig 1. Showing the pre operative photograph

Periodontal examination consisted of measuring pockets at six regions of teeth ie, mesiolabial, midlabial, distolabial, mesiopalatal, midpalatal and distopalatal using UNC-15 probe. Periodontal pockets of > 7 mm was present in upper laterals ie, 12 and 22 numbered teeth.

Fig 2. Showing the Periodontal pocket of 7mm on palatal surface of 22

On further clinical examination of the palatal surface of teeth numbers 12 and 22 a fine groove called **palatogingival groove** was noticed which started at the cingulam and travelled apically and laterally as shown in the figure below.

Fig 3. Showing the palatal surface of 12 and 22 with palatogingival grooves

Further investigations were carried out to measure the pulpal extension of the groove and its apical extension on the radicular surface. Apart from routine Intraoral periapical radiographs and Orthopantamographs, Computed Tomography or CT scan was taken to detect and measure of the palatogingival groove present on the teeth 12 and 22.

Fig 4. Showing the CT scan images, arrows pointing to the grooves

Fig 5. Showing the intraoral periapical radiograph

The phase I periodontal therapy consisted of oral hygiene instructions and scaling and root planing. After reevaluation of phase I therapy, a decision to perform periodontal surgery in the upper anterior region was taken. Papilla preservation flap was raised in the upper anteriors as explained by Takeiet al in 1992.

Fig 6. Showing papilla preservation flap

Fig 7. Showing the palatogingival groove

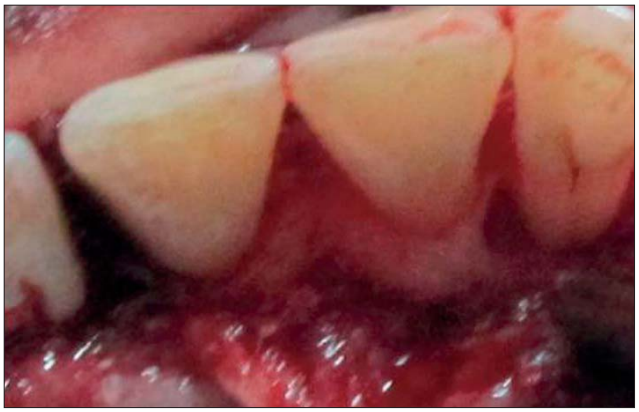

Fig 8. After the groove on 22 being obliterated by odontoplasty

After flap elevation root surfaces were scaled and planed. The palatogingival grooves on 12 and 22 were treated by odontoplasty alone as the pulp was not involved by the palatogingival groove which had been noticed from the CT scan and vitality test was positive. A three wall vertical bony defect present in relation to 22 was treated with reconstructive procedure where a synthetic hydroxyapatite alloplast bone graft material was placed and a re-sorbable collagen membrane was used to cover the bone defect. Then the flap was approximated and sutured with resorbable vicryl 4-0 sutures. Postoperative instructions and medications were given 1). Cap Amox 500 mg tid. 2). Tab Flagyl 400 mg tid 3). Tab Imol plus bid.

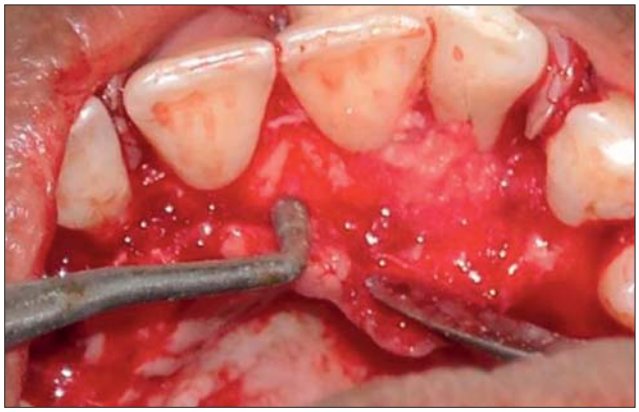

Fig 9. Showing the bone graft placed in the defect

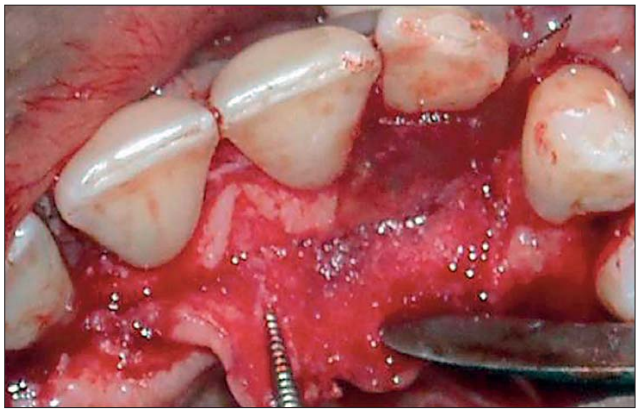

Fig 10. Showing the membrane placed on the defect

There was no postoperative complications and the patient was re evaluated at 1,3,6,9 and 12 months and after 12 months as seen in the figures shown below the healing has been complete with gingiva being healthy and palatogingival grooves are absent.

Fig 11. Post operative photograph after 1 year of surgery, palatal view. Palatogingival grooves are absent

Fig 12. post operative photograph labial view. Gingiva looks healthy

Discussion

The presence of a morphological defect called a palatogingival groove is considered to be an important contributing factor to the development of localized chronic periodontitis, for it favors the accumulation and proliferation of bacterial plaque deep into the periodontium. This anomaly affects maxillary incisors, especially lateral incisors. The prevalence and different morphologic conditions of the palatogingival groove were evaluated by Albaricci MF et al[3] wherein 376 maxillary lateral and central incisors were examined. The teeth were evaluated by a single examiner, considering their presence, localization, origin of formation, extension and depth in millimeters, using a magnifying glass, a precision pachymeter and a millimeter-scaled periodontal probe. Results showed a higher prevalence in lateral incisors with higher prevalence in proximal localization, origination from central fossa (57.1%) and predominance in oblique trajectory (62.8%). Of all these teeth, only 8.6% of palatogingival grooves reached the root apex, while 97.1% were considered as flat (<1mm). Thus, in the presence of a palatogingival groove, periodontal pathologic conditions could be more severe in proximal faces, reaching in a few cases the tooth apex and the pulp canal.

Palatogingival grooves when present may contribute to the pathogenesis of periodontal and endodontic lesions. In the present case there was no endodontic involvement as the CT scan revealed and the teeth was vital. So odontoplasty was used to treat the groove. Also the groove can be filled using glass ionomer cement as explained by Ballal NV et al[4] or Silver amalgam restoration can be done to the groove as explained by Brunsvold MA[5] in 1985. If the teeth with palatogingival groove has an involvement of the pulp either by direct pulpal extension of the groove or apical extension of the groove till the apical foramen then endodontic treatment of the teeth has to be completed first and periodontal treatment has to be carried out.

The presence of palatogingival grooves has led localized periodontal destruction as explained by the epidemological study done by withers et al in 1981. The vertical bone loss due to the periodontal lesion can be treated using bone graft materials as explained by Ballal NV et al[4] and a re-sorbable membrane can also be used for guided tissue regeneration as used by Anderegg CR et al[6]. As in our case there was a presence of bone loss around the teeth 22 only which was treated by bone graft and resorbable membrane. On the otherhand bone loss was not present around 12 and thus treated only by odontoplasty. Thus, if the palatogingival groove does not cause pulpal or periodontal pathology then scaling and root planing with regular re evaluation of the patient and the concerned tooth is the best treatment option.

A combination of endodontic, intentional replantation and Emdogain therapy was used to sucessfully treat a maxillary lateral incisor that had a palatogingival groove by Al-Hezaimi K et al[7] in 2004.

CONCLUSION

Although the incidence of palatogingival grooves is only 8.5%. We should have an eye to recognize them early and diagnose their extent and pulpal involvement in order to save the patient from periodontal destruction

REFERENCES

1. Carranza's Clinical Periodontology, 10th Edition.
2. Withers JA, Brunsvold MA, Killoy WJ, Rahe AJ. The relationship of palato-gingival grooves to localized periodontal disease. J Periodontol. 1981 Jan;**52(1)**:41-44.
3. Albaricci MF, de Toledo BE, Zuza EP, Gomes DA, Rosetti EP. Prevalence and features of palato-radicular grooves: an in-vitro study. J Int Acad Periodontol. 2008 Jan;**10(1)**:2-5.
4. Ballal NV, Jothi V, Bhat KS, Bhat KM. Salvaging a tooth with a deep palatogingival groove: an endo-perio treatment—a case report. Int Endod J. 2007 Oct;40(10):808-17. Epub 2007 Aug 21.
5. Brunsvold MA. Amalgam restoration of a palatogingival groove. Gen Dent. 1985 May-Jun;**33(3)**:244, 246.
6. Anderegg CR, Metzler DG. Treatment of the palato-gingival groove with guided tissue regeneration. Report of 10 cases. J Periodontol. 1993 Jan;**64(1)**:72-74.
7. Al-Hezaimi K, Naghshbandi J, Simon JH, Oglesby S, Rotstein I. Successful treatment of a radicular groove by intentional replantation and Emdogain therapy. Dent Traumatol. 2004 Aug;**20(4)**:226-228.