

REVIEW

## Emergencies in Dental Operatory

Pankaj Agarwal<sup>1</sup> and Ashu Agarwal<sup>2</sup>

Oral Pathology and Microbiology,  
KD Dental College,  
Mathura

Reader<sup>1</sup>  
Lecturer<sup>2</sup>

### Article Info

Received: July 8, 2010

Review Completed: August 10, 2010

Accepted: September 8, 2010

Available Online: October, 2010

© NAD, 2010 - All rights reserved

### ABSTRACT:

ED visits for dental care are on the rise. Some dental conditions can progress to life-threatening complications; stabilizing patients in such cases is incumbent on the emergency physician, as is management of pain and, to some extent, of the dental condition or injury itself. This article reviews basic dental anatomy as well as nontraumatic and traumatic causes of dental pain.

*Key words: Emergencies, dental pain*

### Introduction

The ED is increasingly utilized by patients for dental care. In 2002, approximately 2.7% of ED visits were attributed to dental problems;<sup>1</sup> since then, the circumstances leading to this rate of usage have persisted or worsened. Many patients lack dental insurance, and those who have it often have limited benefits. Furthermore, Medicaid has decreased its dental coverage. According to a recent survey of persons with dental problems, 7.1% visited the ED, 14.3% visited primary care physicians, and 90.2% visited a dental professional.<sup>2</sup> The majority of those who visited the ED ultimately required subsequent visits to the dentist, further increasing the expense. Additional demographic breakdown revealed that patients utilizing the ED for dental care were of a lower income bracket.<sup>2</sup> In California during the period from 2005 to 2007, more than 80,000 ED visits per

year were made for preventable dental problems, with a seven-times higher incidence of visits for those without private insurance.<sup>3</sup> To complicate matters, many physicians do not feel they have adequate training with regard to dental care.<sup>4</sup> In addition, many patients are not aware that physicians typically have very limited training in the care of dental problems. This article reviews common dental problems seen in the ED.

### ANATOMY

The adult mouth may contain up to 32 "secondary" teeth. Children, on the other hand, have only 20 teeth, referred to as *primary* or *deciduous teeth*. The standard numbering system for adult teeth begins with number 1 at the patient's right third molar in the maxilla and continues around the maxilla to number 16. The numbering continues with number 17 on the left third molar in the mandible and continues around the mandible to number 32 on the right side of the mandible (Figure 1).

Email for correspondence:  
drpankajagarwaldentist@yahoo.com

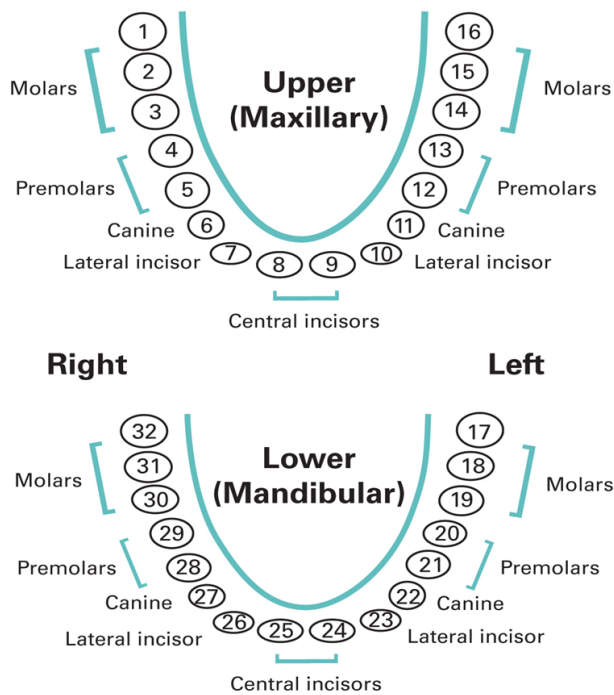


Figure 1. Dental Anatomy

Figure 2 shows a healthy tooth. At its center is the pulp, which contains the tooth's nerves and vascular supply. The pulp is encased in dentin, a yellow substance that is harder than bone and comprises the largest portion of the tooth. At the crown of the tooth, the dentin is enveloped in enamel, while at the root it is covered in cementum. This cementum and the periodontal ligament attach the tooth to the jaw.

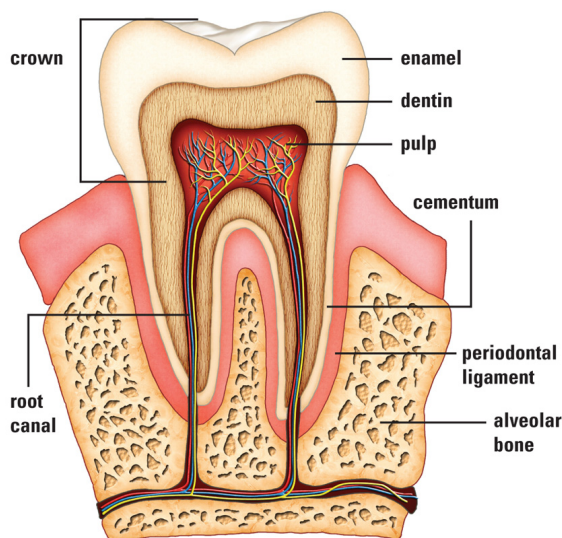


Figure 2. A healthy tooth

## NONTRAUMATIC ORIGINS OF DENTAL PAIN

Decay and abscess are two main causes of dental pain in patients presenting to the ED.

### Dental caries

Dental caries, also known as *cavities*, are disease caused by bacterial breakdown of tooth enamel. Initially, caries are asymptomatic. As the bacteria that constitute the oral flora digest carbohydrates, they produce acids that demineralize the enamel and dentin. Over time, these acids may penetrate to the pulp, triggering transient tooth pain, or reversible pulpitis. The most common organisms include *Peptostreptococcus*, *Bacteroides*, *Peptococcus*, *Fusobacterium*, and *Streptococcus viridans*. Initially, there is often a nonlocalizing, persistent pain, with sensitivity to stimuli such as hot and cold as well as to sweet or sour tastes. If the cavity is not treated by a dentist, irreversible pulpitis may ensue. Treatment of pulpitis requires extraction or root canal within 48 hours of ED presentation to prevent more serious infection. Should definitive dental care be delayed, inflammation of the area around the root, or apical periodontitis, can develop. The resulting pain is localized to the affected tooth and may be elicited by touching, or percussing, the affected tooth. Apical periodontitis left untreated leads to pulp necrosis. Pain can be managed temporarily in the ED with nerve blocks or narcotics until definitive dental care can be provided.

### Periodontal Abscess

Dental abscesses are typically composed of multiple bacteria from normal oral flora.<sup>5</sup> Periodontal abscesses are a complication of untreated periodontitis, arising from the support structure of the tooth. This is the most common adult dental infection.<sup>6</sup> Children are more likely to develop periapical abscesses arising from caries that breach the pulp chamber and continue into the alveolar bone.<sup>7</sup>

### Periapical Abscess

This infection begins within the dental pulp and travels to the alveolar bone via the apical foramen of the tooth. These abscesses usually cause swelling of the face or cheek, since the apices are located on the facial (versus the lingual) side. In severe cases, facial

CT with IV contrast can be used to determine the extent of the abscess.

Periapical abscesses may spread beyond the oral cavity to become deep space or fascial space infections, which have the potential to cause airway obstruction. Clinical signs that infection has spread beyond the oral cavity include swelling of the floor of the mouth or tongue, dyspnea, eye swelling, or trismus. In particular, dental abscess extension along the maxillary canine teeth may cause eye swelling. Should swelling reach the eye or raise concern for airway obstruction, an oral surgeon should be contacted immediately; hospitalization for extraction and IV antibiotics may be warranted.

### Abscess Management

Radiologic imaging can be useful to evaluate the extent of disease. A panoramic radiograph of the mandible (Figure 3) can document the extent of bony involvement as well as localize the abscess. An abscess will appear as lucency or bony destruction. Table 1 provides guidance for the evaluation of a panoramic radiograph.<sup>8</sup>

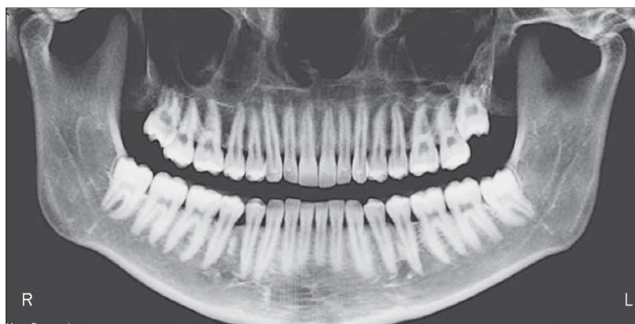

Figure 3. Panoramic Radiograph

Table 1. Review of Panoramic Radiograph

- Evaluate the lower border and look for bone cortical deformity.
- Look for broken or missing teeth.
- Look at spacing between upper and lower teeth; spacing that appears off balance may indicate condylar neck fracture.
- Evaluate the maxilla and mandible edges for "step off"

Patients presenting with fluctuant abscesses should undergo incision and drainage by the emergency physician. This first involves obtaining anesthesia of the area, which is best achieved by a nerve block using bupivacaine or lidocaine.

### Nerve Blocks

In all of the nerve blocks described here, a 25- or 27-gauge needle is used with bupivacaine 0.25% plus epinephrine. The duration of anesthetic relief is about 9 hours for the soft tissues and 3 hours for the dental pulp.

The *inferior alveolar nerve block* achieves anesthesia of the mandibular teeth and anterior two-thirds of the tongue; however, it is difficult to administer. The process is as follows: (1) place topical anesthetic (optional); (2) place thumb of nondominant hand in edge of the mouth notch at the angle where the upper and lower lip connect, then place the index finger at the coronoid notch of the jaw; (3) place the syringe parallel to the surface of the teeth with the barrel of the syringe resting diagonally on the opposite corner of the mouth; (4) aiming toward the index finger, insert and advance the needle about 2.5 cm, allowing the needle to contact bone; (5) withdraw slightly and aspirate. If no blood is observed, inject 2 mL of anesthetic. Figure 4 depicts administration of this block.

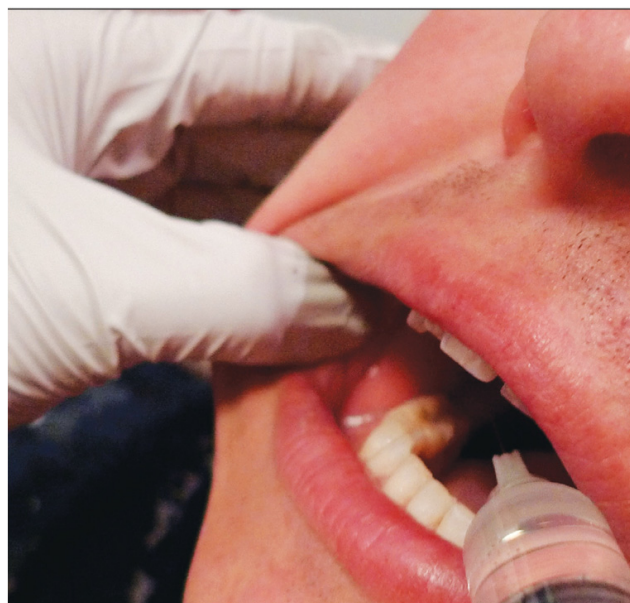
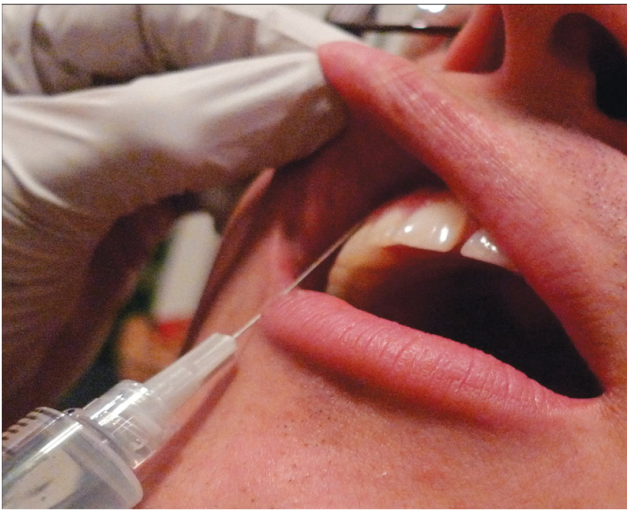
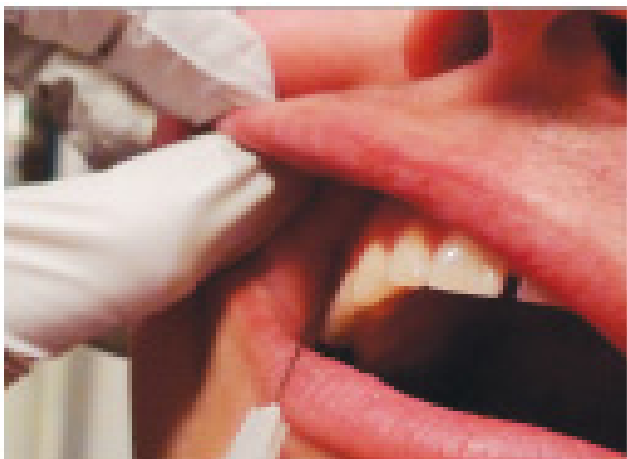
Figure 4. Inferior Alveolar nerve block

The *anterior superior alveolar nerve block* is used to obtain anesthesia of the maxillary canine and central and lateral incisors. It is administered as follows: (1) locate the canine and insert the needle into the mucobuccal fold at mid canine at approximately 45°; (2) advance the needle about 1.5 cm; (3) aspirate, and if no blood is observed, inject 2 mL of anesthetic. Figure 5 shows the administration of this block.



**Figure 5.** Anterior superior alveolar nerve block

The *middle superior alveolar nerve block* is used for the maxillary premolars and first molar. It is performed as follows: (1) insert the needle into the mucobuccal fold between the last premolar and first molar at 45°; (2) advance the needle about 1.5 cm; (3) aspirate, and if no blood is observed, inject 2 mL of anesthetic. Figure 6 depicts administration of this block.



**Figure 6.** Middle superior alveolar nerve block

The *posterior superior alveolar nerve block* is used to obtain anesthesia of the molars; however, this block may not achieve complete anesthesia in the first molar. If this is the case, the middle superior alveolar nerve block should be added. The posterior superior alveolar nerve block is administered as follows: (1) insert the needle into the mucobuccal fold between the first and second molars at 45°; (2) advance the needle about 2 cm, following the maxilla toward the maxillary tuberosity; (3) aspirate, and if no blood is observed, inject 2 mL of anesthetic.

### **Draining the Periodontal Abscess**

Once proper anesthesia is achieved, aspiration of the abscess should be attempted using an 18-gauge needle. If pus is aspirated (confirming the abscess), some pus should be left un-aspirated for easier localization. An incision is made over the abscess with a #11 blade scalpel, and the purulence is allowed to drain. Packing is not necessary. If no pus is aspirated, medical management with antibiotics is warranted until an abscess forms. If available, ultrasound can be utilized in lieu of needle aspiration to verify the presence of an abscess. New studies are under way, comparing the use of ultrasonography and panoramic radiography to visualize the extent of disease; findings from a 2009 study suggest that bedside ultrasound is a useful alternative to the panoramic x-ray.<sup>8</sup> For cases involving fever or signs of toxicity, treatment with doxycycline (100 mg orally twice daily for 10 days) or penicillin has been shown to decrease the duration of swelling by 2 to 3 days.<sup>9</sup> Pain may be managed with narcotics or anti-inflammatory agents.

### **Other Complications and Nontraumatic Causes of Pain**

#### **Ludwig Angina**

Ludwig angina is a rare, dangerous complication of an initially minor dental infection. Often developing quickly, even within 48 hours, the condition occurs when the submental, sublingual, and submandibular spaces become infected. The patient presents with significant tongue elevation (due to edema of the sublingual tissue) and bilateral submental and submandibular neck swelling. This infection can rapidly progress to complete airway

obstruction and may even track into the chest wall, causing mediastinitis. Management involves early recognition of potential airway obstruction and immediate initiation of antibiotics and steroids.

Airway management in Ludwig angina is controversial. Although there is a possibility of complete airway obstruction as the infection progresses, the process of securing the airway may cause complications, such as rupture of pus into the airway. Traditional direct laryngoscopy may be impossible to perform due to airway edema. Awake nasotracheal intubation with a fiberoptic scope may be the best method.<sup>10</sup> Should this fail, surgical airway management is necessary. Ultimately, patients will require ICU admission and otolaryngologic consultation.

### **Lemierre Syndrome**

Also a rare entity, Lemierre syndrome is a thrombophlebitis that develops as a complication of an oropharyngeal infection. It begins with fever, sore throat, neck pain, trismus, and swelling, but unlike Ludwig angina, it also causes septicemia, often affecting the internal jugular vein. Infectious embolic lesions may travel via the internal jugular vein to the lungs, joints, or bones and may cause severe sepsis or formation of a brain abscess. Other complications such as meningitis and cavernous sinus thrombosis must be considered if the patient presents with a headache in addition to the signs and symptoms mentioned above. The most common causative organism is *Fusobacterium*, and treatment involves long-term IV antibiotic therapy.<sup>11</sup>

### **Trench Mouth**

Acute necrotizing ulcerative gingivitis (ANUG) is an aggressive form of gingival disease that involves pain, ulcerations, bleeding, and malodorous breath. Severe cases of ANUG result in pseudomembrane formation. ANUG often results from an opportunistic infection occurring in individuals with immune system disorders. Treatment involves chlorhexidine rinses, debridement, and metronidazole.<sup>12</sup>

Periodontal diseases are in general of bacterial origin and are often seen when chronic plaque is involved and proper hygiene is lacking. The teeth may become loose and painful and an abscess may

develop. Treatment consists of debridement by a dentist. Saline and chlorhexidine mouthwashes are helpful.<sup>13</sup>

### **Dry Socket**

Alveolar osteitis may develop 24 to 48 hours after extraction of a permanent tooth. It occurs when the blood clot at the extraction site is disrupted, exposing the alveolar bone and nerve endings to air, which causes exquisite pain. Treatment includes saline rinses to remove any debris and use of oil of cloves packing. This condition requires dental follow-up in 24 hours.

### **Tooth Eruption**

As the tooth pushes through the gum, it causes pain and low-grade fevers (<37.9°C). If food is entrapped, pericoronitis may develop, especially with wisdom tooth eruption. Treatment consists of saline rinses, penicillin, and dental follow-up. In severe cases, anti-inflammatories or narcotics may be used until pain subsides.

## **DENTAL TRAUMA**

Accidents and sports are the leading cause of dental trauma. Level of injury ranges from minor pain and sensitivity to complete loss of the tooth and facial fracture. Pain control and early dental follow-up are key to management.

### **Dental Fractures**

Tooth fractures are classified according to the Ellis system. Ellis class I fractures involve the enamel only. Treatment is nonemergent smoothing of sharp edges. Ellis class II fractures involve the enamel and the dentin, which is identified by its yellow color. The exposed dentin is very sensitive. In Ellis class III fractures, the pulp is exposed and blood can be visualized. Emergent treatment of class II and III fractures requires covering the fractured area with calcium hydroxide dental cement. Both class II and III fractures require dental follow-up within 24 hours to preserve the pulp, and topical analgesics are not recommended. Ultimately, root canal or endodontic therapy is required. In class IV fractures, or fractures of the root, extraction by a dentist is indicated. The root may be salvageable if less than one-third is affected.

## **Luxation**

Luxation refers to loosening of the tooth. It can occur with varying degrees of severity.

### **Concussion and Subluxation**

With concussion injury, the tooth is tender to palpation but does not move excessively. The subluxed tooth moves when palpated but is not dislodged. Management of these injuries involves soft diets, NSAIDs, and dental follow-up.

### **Lateral Luxation**

Management of a laterally displaced tooth with alveolar bone fracture depends on the severity of the fracture. A temporary splint is acceptable for small fractures, but larger fractures require stabilization performed in the ED by a dentist. For proper implantation and splinting, adequate anesthesia is important.

### **Intrusive Luxation**

In this injury, the tooth is pushed into the alveolar bone, causing fracture. There is often great damage to the periodontal ligament, and in many cases the root is reabsorbed. The tooth should be left to erupt on its own in 3 to 4 weeks, with anti-inflammatories or narcotics given for pain.<sup>14</sup>

### **Avulsion**

This injury, involving complete displacement of a tooth from its socket, is a true dental emergency. In management of these injuries, "time is tooth"—or more specifically, survival of the periodontal ligament fibers for reimplantation decreases with time. About 16% of dental emergencies involve avulsion, and 21% of avulsions involve the incisors.<sup>15</sup> If the tooth cannot be located, a chest radiograph is warranted to exclude aspiration.

If the patient is unlikely to aspirate the tooth, it should be reimplanted in the field, if possible, after it has been rinsed with saline or tap water. The tooth should be protected, and the roots should not be touched. The tooth should not be scrubbed, so that any remaining viable cells may remain intact. If transport is required because of concern that the patient will swallow/aspirate the tooth, the tooth should be placed in Hanks balanced salt solution,

saline, or milk. Placing the tooth in sports beverages or contact lens solution is not advised.

In the ED, the tooth should be rinsed with Hanks solution or saline and the socket should be irrigated for clot removal. There are differing opinions on the value of presoaking a tooth that has been dry for 20 to 60 minutes, versus reimplanting it immediately. Some studies recommend soaking in Hanks solution for 30 minutes prior to reimplantation,<sup>15</sup> but the American Dental Association favors immediate reimplantation.<sup>16</sup> Research demonstrates that presoaking in doxycycline 1 mg diluted with 20 mL of water for 5 minutes may aid in dental revascularization.<sup>15</sup> A tooth that has been dry for more than an hour is unlikely to have viable periodontal fibers remaining. If reimplantation is attempted, the tooth should be soaked for 5 minutes in doxycycline prior to reimplantation to slow inflammation. However, soaking the tooth in doxycycline has only a theoretical benefit and has not been shown to improve outcomes. After the tooth is reimplanted, it should be splinted with suture or splint material as discussed below.

### **Extrusion**

A tooth that is partially dislodged from the alveolar bone requires replacement and splinting; anesthetic and clot removal may be needed as well. Treatment involves irrigation of the dental socket using saline and an angiocatheter until any clot dislodges. The tooth should then be properly repositioned and splinted. Dental follow-up is required, and splinting should remain in place for 1 to 2 weeks.

### **Temporary Tooth-Splinting**

Some splints are available in premixed solution, while others require mixing. When the dressing has been prepared according to package directions, it should be molded over the gum line and between the teeth.

### **Pediatric Considerations**

In certain cases, management of dental trauma in children differs from that in adults. Luxation of baby teeth does not affect speech or development of permanent teeth; affected baby teeth should be removed, as they can be aspirated. Likewise, avulsed

teeth should not be replaced, but a radiograph should be obtained to evaluate for intrusion or aspiration. Fractures in children should be treated similarly to those in adult teeth. As in adults, root fractures in children may require extraction; however, these injuries are quite uncommon.<sup>17</sup>

## CONCLUSION

Dental pain and trauma account for a significant proportion of ED visits. For many dental emergencies, management involves identifying the underlying cause, determining the extent or severity of the condition, and performing minor procedures, such as draining an abscess or splinting a loose tooth, followed by referral to a dentist for definitive treatment.

## REFERENCES

1. Cohen LA, Manski RJ, Magder LS, Mullins CD. Dental visits to hospital emergency departments by adults receiving Medicaid: assessing their use. *J Am Dent Assoc.* 2002;133(6):715-724.
2. Cohen LA, Bonito AJ, Eicheldinger C, et al. Comparison of patient visits to emergency departments, physician offices, and dental offices for dental problems and injuries. *J Pub Health Dent.* 2010 Aug 17 [Epub ahead of print].
3. California Healthcare Foundation. Snapshot: Emergency Department Visits for Preventable Dental Conditions in California, 2009. <http://www.chcf.org/~media/Files/PDF/E/EDUseDentalConditions.pdf>. Accessed September 13, 2010.
4. Lin S, Levin L, Emodi O, et al. Physician and emergency medical technicians' knowledge and experience regarding dental trauma. *Dent Traumatol.* 2006;22(3):124-126.
5. Robertson D, Smith AJ. The microbiology of the acute dental abscess. *J Med Microbiol.* 2009; 58(2):155-162.
6. Lewis C, Lynch H, Johnston B. Dental complaints in emergency departments: a national perspective. *Ann Emerg Med.* 2003;42(1):93-99.
7. Oliva MG, Kenny DJ, Ratnapalan S. Nontraumatic dental complaints in a pediatric emergency department. *Pediatr Emerg Care.* 2008;24(11):757-760.
8. Adhikari S, Blaivas M. 216: Comparison of bedside ultrasound and Panorex radiography in the diagnosis of a dental abscess in the emergency department [ACEP abstract 216]. *Ann Emerg Med.* 2009;54(3)(suppl 1):s67.
9. Rodriguez DS, Sarlani E. Decision making for the patient who presents with acute dental pain. *AACN Clin Issues.* 2005;16(3):359-372.
10. Ovassapian A, Tuncbilek M, Weitzel EK, Joshi CW. Airway management in adult patients with deep neck infections: a case series and review of the literature. *Anesth Analg.* 2005;100(2):585-589.
11. Lee BK, Lopez F, Genovese M, Loutit JS. Lemierre's syndrome. *South Med J.* 1997;90(6):640-643.
12. Wayne DB, Trajtenberg CP, Hyman DJ. Tooth and periodontal disease: a review for the primary-care physician. *South Med J.* 2001;94(9):925-932.
13. Douglass AB, Douglass JM. Common dental emergencies. *Am Fam Physician.* 2003;67(3):511-516.
14. Diangelis AJ, Bakland LK. Traumatic dental injuries: current treatment concepts. *J Am Dent Assoc.* 1998;129(10):1401-1414.
15. Trope M. Clinical management of the avulsed tooth. *Dent Clin North Am.* 1995;39(1):93-112.
16. Dental emergencies. American Dental Association Web site. <http://www.ada.org/370.aspx>. Accessed September 13, 2010.
17. Bruns T, Perinpanayagam H. Dental trauma that requires fixation in a children's hospital. *Dent Traumatol.* 2008;24(1):59-64.

Write to us your valuable comments  
and  
suggestions at  
**editorijda@gmail.com**