

CASE REPORT

A Prosthodontic Rehabilitation of a Partial Maxillectomy Patient with Hollow Bulb Obturator

Kiran Kumar Thota¹, Suchita Tella², Anulekha Avinash CK³, Rajyalakshmi Ravuri⁴

Department of Prosthodontics and Implantology,
Kamineni Institute of Dental Sciences and Research
Sreepuram, Narkatpally,
Dt: Nalgonda, A.P

Assistant professor ^{1, 2, 3, 4}

Article Info

Received: July 13, 2010

Review Completed: August 15, 2010

Accepted: September 10, 2010

Available Online: October, 2010

© NAD, 2010 - All rights reserved

ABSTRACT:

Rehabilitating patients with maxillofacial defects is one of the most difficult therapies of the stomatognathic system. Maxillary defects being the most common of these defects need to be rehabilitated to restore the lost form, function and speech. Prosthetic reconstruction of these defects may be made with the help of obturator prosthesis. The present case report describes the steps in the fabrication of hollow bulb obturator prosthesis.

Key words: maxillofacial defects, hollow bulb obturator, prosthetic reconstruction

INTRODUCTION

Maxillofacial defects may be a result of congenital malformations, trauma or surgical resection of tumors. The primary objective of rehabilitating these defects is to eliminate the disease and to improve the quality of life for these individuals.¹ Among various maxillofacial defects, intra oral defects in the form of clefts and opening into the palate are very common. Several methods have been advocated for reconstructing these defects. The use of an obturator prosthesis is one of them. According to the glossary of prosthodontic terms obturator is defined as prosthesis used to close a congenital or an acquired tissue opening, primarily of hard palate and or contiguous alveolar structures. The name obturator is derived from the Latin verb "obturare" which means close or to shut off.²

Email for correspondence:
Thotakiran21@gmail.com

Effective obturation of maxillary defects produces sufficient separation of the oral and nasal cavity to improve the quality and intelligibility of speech. It also enhances masticatory function, deglutition and esthetics. The weight of maxillary obturator prosthesis is often a factor to be considered with respect to retention and comfort of the patient. Hence it is desirable to design light weight prosthesis. Prosthetic intervention should occur at the time of surgical resection and will be necessary for the remainder of the patients life.^{3,4}

This clinical report describes the fabrication of hollow bulb obturator prosthesis for a patient with a maxillary defect after undergoing partial maxillectomy procedure.

CASE REPORT:

A nineteen year old male patient reported to the Department of Prosthodontics with a swelling on the

right side of the palate. The patient was referred from the oncology department after being diagnosed for squamous cell carcinoma. A surgical resection of the tumor was planned which was to be followed with prosthetic rehabilitation. (fig 1)

Diagnostic impressions of maxillary and mandibular arches were made for the fabrication of a pre surgical obturator, which could act as a surgical stent. The patient was then operated and the tumor was resected. The surgical resection also included a part of the palate and the following teeth 7, 16, 15. The surgical obturator was worn for a period of 7 days, following which the patient was given a series of interim obturators until a satisfactory healing of the tissues was achieved. After this definitive obturator prosthesis was planned for the patient.

Definitive prosthesis:

A perforated stock tray was selected for making the preliminary impression. The stock tray was modified using impression compound corresponding to the area of the defect. Primary impression of the maxillary arch was made using putty relin technique and the mandibular arch was recorded using alginate.

The primary casts were obtained from the impression. These casts were surveyed and the necessary mouth preparation was performed on the patient before making secondary impression. Cast partial denture design of the prosthesis was finalized and the framework was fabricated. (fig 2) Then the framework was tried in the patient's mouth to check for the fit.

At this stage the framework was used as a tray to record the defect area using putty relin technique. A pick up impression of the remaining natural teeth were made using alginate. The impression was then poured following which the framework was separated from the cast. At this stage a denture base was fabricated and the jaw relations were recorded. The missing teeth were arranged and try in procedure was performed. (fig 3)

Fabrication of the hollow bulb:

The trial denture was then sealed to the master cast. After application of the separating media on the cast, the counter portion was poured. Since the defect area was too large, a conventional flask could not be used. Hence the base portion of the cast as well as the counter portion was made thicker using boxing wax. (Fig 4). This was followed by the dewaxing procedure.

After separation of the counter parts, a layer of modeling wax was adapted in to the defect area, which provided the space for heat cure resin to flow between the bulb and the defect portion of the cast. Three tissue stops were created in the wax which prevented the tissue ward movement of the prosthesis in to the defect. Auto polymerizing clear acrylic resin was adapted over the wax to fabricate a shim (fig 5). The wax was eliminated and the shim was filled with sugar crystals. A lid was made and sealed to the shim to make it a bulb. A small escape vent was created in the bulb using a straight fissure bur. It was then placed in a bowl of water to dissolve the sugar crystals. Hence making the bulb hollow.⁴ (fig 6)

The hollow bulb was placed back into the defect. A clearance of 1mm was seen between the outer layer of the bulb and the defect, which was to be occupied by the heat cure resin. The framework and the bulb were placed back on the cast and checked for any interference.

Following this separating medium was applied on to the cast and the counter portion. Heat cure resin was adapted in to the defect area after which the hollow bulb and the framework were placed back in to their respective position on the cast. The heat cure resin was also packed in to the mould space and the two parts were clamped. Together this unit was subjected to the regular curing cycle.

Following deflasking procedures, the prosthesis was trimmed, finished, polished and inserted in to the patient's mouth after minor corrections. (fig 7 & 8)

Post insertion instructions were given and the patient was taught how to use the prosthesis. The patient was called after 24 hours for the check up. Recall visits were also scheduled after 1 week, 1 month, 3 and 6 months.

Discussion:

A hollow bulb obturator was fabricated for the patient mentioned in this case report. After surgical resection, the defect could be categorized under Armany class II situation.^{5,6,7} Based on this the cast partial framework was designed with the required components.

The regular palatal strap major connector was modified in order to achieve a greater support from the palate, as the defect was large. The metal framework provided good retention, support and stability. The longevity of the prosthesis could be attributed to the strength of the metal. Further, the thermal conductivity of the metal made it sensitive to the temperature changes and the patient showed better functional acceptance to the prosthesis.⁸

A hollow bulb design for the obturator was chosen in order to reduce the bulk of the prosthesis which in turn made it light weight and more comfortable for the patient. The hollow bulb further added resonance, thus improving the clarity of the speech.^{9,10} The present prosthesis not only improved the speech and function but also provided better comfort for the patient.

Summary:

The present case report showed the prosthetic rehabilitation of a partial maxillectomy patient using a hollow bulb definitive obturator. It involved the fabrication of a cast partial denture framework onto which a hollow bulb prosthesis was made. The prosthesis rehabilitated the patient in terms of function by providing better masticatory efficiency, phonetics by adding resonance to the voice hence improving the clarity of speech and also improved the esthetics of the patient. The use of a hollow bulb

design improved the comfort of the patient by decreasing the weight of the prosthesis.

References

1. Lethaus B, Lie N, de Beer F, Kessler P, de Baat C, Verdonck HW. Surgical and prosthetic reconsiderations in patients with maxillectomy. *J Oral Rehabil.* 2010 Feb;**37**(2):138-42.
2. Glossary of prosthodontic terms 2008.
3. Taylor T D. Clinical maxillofacial prosthetics. Quintessence Publishing Co, Inc. Pg :85-102.
4. Chalian. Maxillofacial prosthetics. Elsevier publication, p.
5. Aramany MA. Basic principles of obturator design for partially edentulous patients. Part I: Classification. *J prosthet dent* 2001;**86**(6), 559-561.
6. Aramany MA. Basic principles of obturator design for partially edentulous patients. Part II: Design principles. *J prosthet dent* 2001;**86**(6), 562-568.
7. Gregory RP, Gregory ET, and Arthur OR, Prosthodontic principles in the framework design of maxillary obturator prostheses. *J Prosthet Dent* 2005;**93**:405-411
8. Mc crackens. Removable Partial Prosthodontics. 11th ed, Mosby Elsevier, p.79-107.
9. Russell RW, and Robert FH. Refining hollow obturator base using light-activated resin. *J Prosthet Dent* 1997;**78**:327-329.
10. B.Rilo, j.L. Dasilva, i.Ferros, m.J.Mora & u.Santana. A hollow-bulb interim obturator for maxillary resection- Acase report. *Journal of Oral Rehabilitation* 2005 **32**; 234—236.
11. Yoav Grossmann, and Igal Savion. The use of a light-polymerized resin-based obturator for the treatment of the maxillofacial patient. *J Prosthet Dent* 2005;**94**:289-292.
12. Mark A. Pigno, Conventional prosthetic rehabilitation after free flap reconstruction of a maxillectomy defect: A clinical report. *J Prosthet Dent* 2001;**86**:578-581.
13. Won-suck Oh & Eleni D. Roumanas. Optimization of Maxillary Obturator Thickness Using a Double-Processing Technique. *Journal of Prosthodontics.* 2008, **17**: 60—63.
14. Beumer J, Curtis TA, Firtell DN. Maxillofacial rehabilitation. St. Louis: Mosby; 1979. p. 188-243.

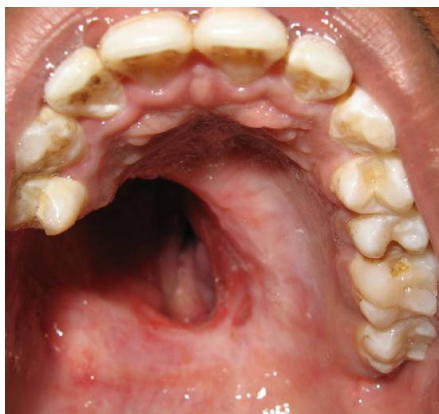

Figure 1: Intraoral View of the Defect

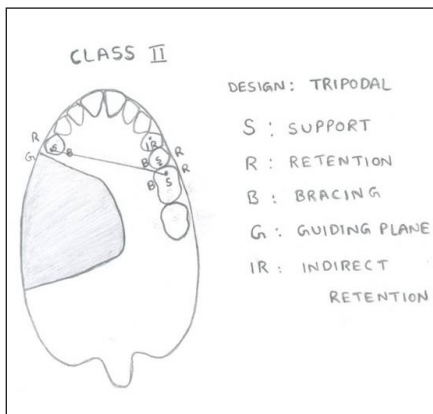


Figure 2: Design of the Cast Partial Denture

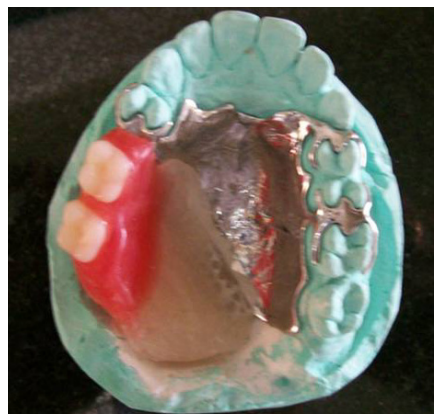

Figure 3: Trial Denture



Figure 4: Flasking Technique

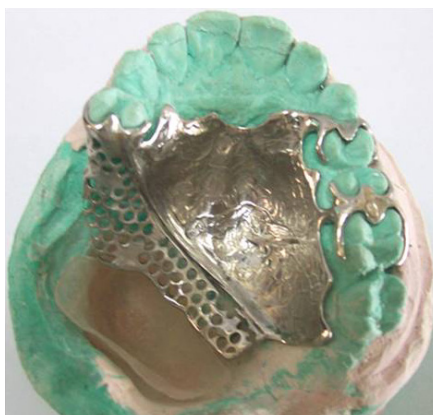

Figure 5: Fabrication of a Shim



Figure 6: Hollow Bulb

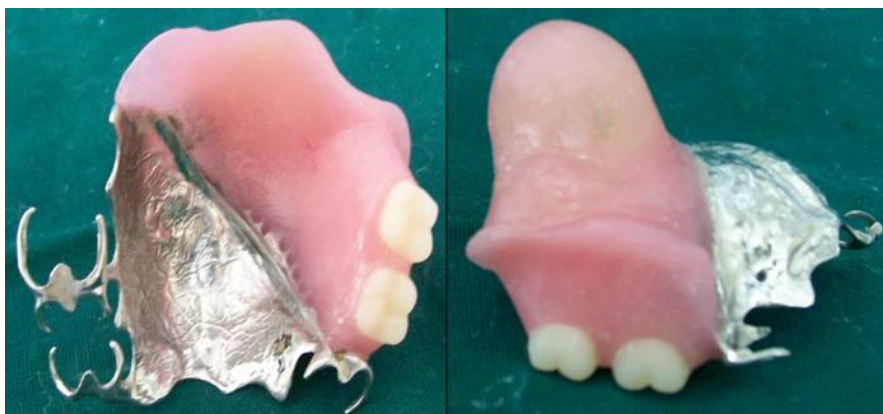

Figure 7: Hollow Bulb Obturator

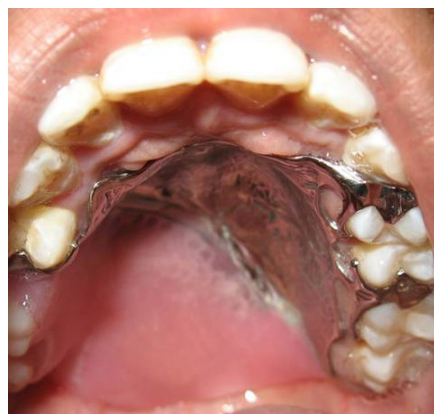

Figure 8: Intraoral view of the Obturator