

CASE REPORT

Mechanical complications with implants and implant prostheses

Gita Malathi K¹ and Ravi Chandra PV²

Sr. Lecturer¹

Department of Periodontics,
S.V.S. Dental College and Hospital,
Mahboob Nagar-509001
Andhra Pradesh, INDIA

Professor & HOD²

Department of Conservative Dentistry
Kamineni Institute of Dental Sciences,
SriPuram, Narketpally - 502854
Andhra Pradesh, INDIA

Article Info

Received: January 14, 2011

Review Completed: February 17, 2011

Accepted: March 19, 2011

Available Online: July, 2011

© NAD, 2011 - All rights reserved

ABSTRACT:

Adverse occlusal forces can result in mechanical complications of implant components. An implant fracture may be one of the major causes of implant failures. Complications, such as loosening or fracture of the prosthesis restorative components, or even fracture of the implant, may occur and dental professionals should be aware of the causes of these complications. Most implant complications are due to technical problems like screw loosening, screw fracture, fracturing of veneering porcelain and framework fracture in implant-supported fixed partial dentures (FPDs). This case report presents complications that were seen after prosthodontic rehabilitation with implants in the left upper posterior maxilla. Radiographs and clinical data are presented that document the complications of loosening of components of implant system. After final ceramic crown prosthesis for the implant was done, clinically the loosening of abutment with the crown from implant was seen after 15 days. Radiograph of the area revealed microgap between the abutment and the implant. This case highlights one of the common technical complications ie; loosening of the abutment screw in implant dentistry. Managing this complication can cause extra amount of chair-side time and patient dissatisfaction, and should be prevented.

Key words: *Implants, Mechanical complications, Screw Loosening, Microgap*

INTRODUCTION

The high predictability and long-term success of implant therapy has been well documented (Adell 1981, Albrektsson 1986). Complications do arise, as it may be the case after any prosthodontic or surgical procedure. In recent years, a number of authors have specifically looked at implant related complications and maintenance requirements.¹ The complications have been divided into the following 6 categories: surgical, implant loss, bone loss, peri-implant soft tissue, mechanical, and esthetic/phonetic. Improper selection of patient is another reason negatively

affecting the above mentioned reasons of dental implant failure.

Once osseointegration is established, complications can be divided into biological and mechanical ones. The literature has reported biological complications which may include adverse soft tissue reactions, sensory disturbances, progressive marginal bone loss and loss of integration. Mechanical complications may include fractures or loosening of components in the system. Thorough understanding of the etiology and the frequency of these complications is lacking due to the failure of establishing standardized methods of data collection.¹

Email for correspondence:
gitamalathi@yahoo.co.in

CASE REPORT

A 31-year old male patient came to the Department of Periodontics, with a missing upper left canine (tooth 23) and a grade III mobile upper left first premolar (tooth 24). Extraction of 24 & replacement at 23, 24 was planned and implant therapy was given as an option. After informed consent, comprehensive periodontal examination and routine pre-surgical and radiographic investigation were done (Fig 2). After proper case analysis, a two-stage implant placement was planned. Prophylactic antibiotics & analgesics were prescribed before stage one surgery and a surgical stent was prepared.

Implant placement was done in 23 & 24 region using 13 mm long tapered implants[†] (UNITI-Equinox Pvt Ltd, Holland) of 3.7mm and 4.3 mm diameters, respectively (Fig3). # 23 region was simultaneously, horizontally grafted with porous hydroxyapatite (Alloplast). After proper flap approximation, post operative instructions given and patient was recalled for review. At 6th month recall or second stage of surgery, the implants were exposed and gingival formers were placed (Fig 4). On the 7^{1/2}th month recall, a metal healing abutment (collar) replaced the gingival formers (Fig5) and an impression was made with Rubber base material using a two stage impression technique for final prosthesis.

Final ceramic crown prosthesis were placed in 23, 24 region (Fig6). 15 days after insertion, loosening of crown in relation to 24 was clinically seen (Fig7). IOPA radiograph of 24 revealed that a microgap between the abutment and the implant (Fig8). When the same abutment minus crown was retried, there was a microgap identified clinically between abutment & implant (Fig9). The case was recall for analysis of the problem & its rectification (Fig10).

DISCUSSION

Failures and complications with implant and abutment components as well as with materials of the prostheses result in frequent repairs and even remakes. Mechanical complication and fatigue of implant components is considered a sequel of biomechanical overload.² Other complications

involve screw loosening, screw fractures, cement failure, etc. The rate of technical complication is higher in fixed partial dentures on implants.³ Jemt et al have stated that a significantly higher ratio of problems was identified in the maxillae than for the mandibles. Though most problems are common to both, there are also problems more typical for each jaw. Diction and fractures of resin teeth were more common problems in maxillae; cheek and lip biting was a more frequent post-insertion complication in the treatment of mandibles.⁴

In a literature review by Goodacre et al, abutment screw loosening was reported to range between 2% to 45 %. The highest rate was found with single crowns followed by overdentures whereas prosthetic screw loosening ranged from 1% to 38%. The etiology of the screw loosening is most likely multifactorial. Factors that have been attributed to screw loosening are: occlusion, prosthesis fit as well as screw design and composition (Cooper & Moriarty, 1997).⁵

In the present case loosening of the abutment with the crown from implant was seen in the first premolar region. This may be due to (1) more sub crestal positioning of implant in that specific site (due to lack of bone density in that particular area), (2) improper positioning or fixation of abutment with the implant, or (3) over occlusive forces in the second premolar region which eventually lead to loosening of crown with 24. Proper fixation of the abutment with the implant is crucial to the success of the implant prosthesis⁶. Care should be taken to avoid improper fixation in order to prevent microgaps and loosening of prosthesis that might be due to excessive occlusal forces or improper positioning of abutment or screw loosening. Implant failures due to the above reasons can thus be avoided. Research and clinical results indicate that cautious timing of site preparation and implant placement, along with important concepts of implant spacing, can significantly reduce complications.⁷

Over the years, manufacturers have modified implant components in order to mitigate the problem of screw loosening. Unacceptably high incidences of mechanical failures (abutment screw loosening and fracture) due to adverse occlusal

forces have been eliminated by the 8 degrees Morse taper. The incidence of prosthetic screw loosening has been minimized by the 45 degrees bevel on the implant shoulder and by the 1.5 mm vertical abutment walls.⁸ The transition to gold-alloy screws has allowed a more effective tightening to higher preloads due to its lower coefficient of friction than titanium (Binon, 2000). In an effort to further reduce frictional resistance, dry lubricant coatings have been applied to abutment screws. The reported data indicate an effective increase in attainable preload. However, the effectiveness of this technology on screw joint stability has yet to be fully documented with independent research and in clinical trials.⁹

CONCLUSION

Screw loosening is usually detected at recall examinations with mobility testing and/or radiographic examination. They can be an inconvenience to the patient and the practitioner but more importantly, some authors believe that they are signs of impending failure of other components. It remains unclear exactly what clinical parameters promote the screw loosening encountered by many investigators. However, routine retightening at recall examinations is recommended.

REFERENCES

1. Jim Yuan Lai and Francine Albert. Periodontics: Implant Complications and Maintenance, <http://www.oralhealthjournal.com/issues/ISarticle.asp?aid=1000153058>
2. Kevin Stith. Dental Implant Failure. http://EzineArticles.com/?expert=Kevin_Stith
3. Urs Brägger, Sabine Aeschlimann, Walter Bürgin, Christoph H. F. Hämmerle, Niklaus P. Lang. Biological and technical complications and failures with fixed partial dentures (FPD) on implants and teeth after four to five years of function. *Clin Oral Implants Res* 2001;**12(1)**:26-34.
4. Jemt T. Failures and complications in 391 consecutively inserted fixed prostheses supported by Brånemark implants in edentulous jaws: a study of treatment from the time of prosthesis placement to the first annual checkup. *Int J Oral Maxillofac Implants* 1991;**6(3)**:270-276.
5. Marion E. Kreissl, Thomas Gerds, Robert Muche, Guido Heydecke and Jörg R. Strub. Technical complications of implant-supported fixed partial dentures in partially edentulous cases after an average observation period of 5 years. *Clin Oral Implants Res* 2007;**18 (6)**:720-726.
6. Berglundh T, Persson L, Klinge B. A systematic review of the incidence of biological and technical complications in implant dentistry reported in prospective longitudinal studies of at least 5 years. *J Clin Periodontol* 2002;**29(suppl 3)**:197-212.
7. Renouard F, Nisand D. Impact of implant length and diameter on survival rates. *Clin Oral Implants Res* 2006;**17(suppl 2)**:35-51
8. Schwarz MS. Mechanical complications of dental implants. *Clin Oral Implants Res* 2000;**11(Suppl 1)**:156-158.
9. Elsevier B.V. Clinical complications with implants and implant prostheses. *The Journal of Prosthetic Dentistry* 2009;**90(2)**:121-132.

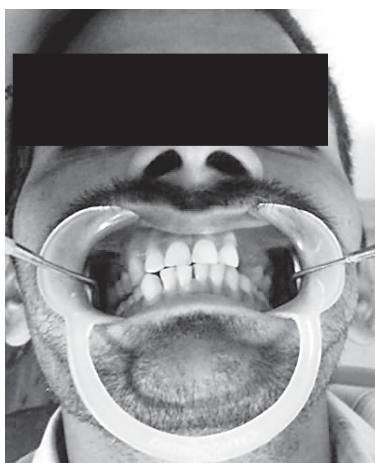

Figure 1: Pre- Operative Clinical view

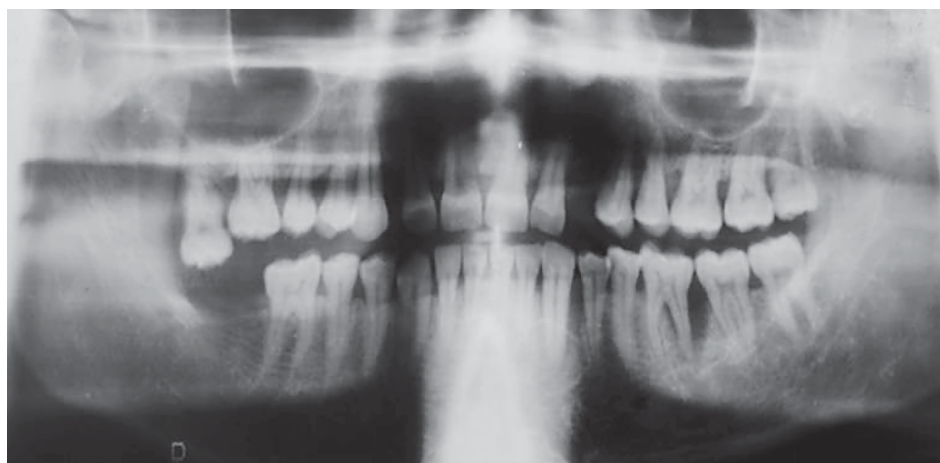


Figure 2: Pre-operative OPG

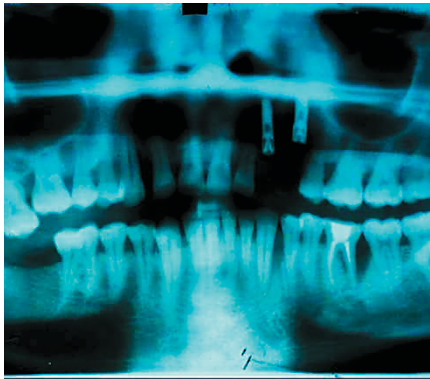


Figure 3: Post-operative OPG after extraction of 24 & implant placement at 23,24 region

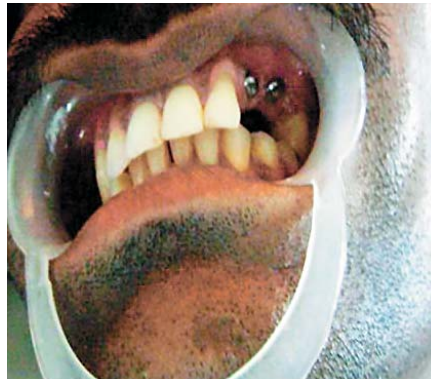

Figure 4: Gingival former placement at 6-month

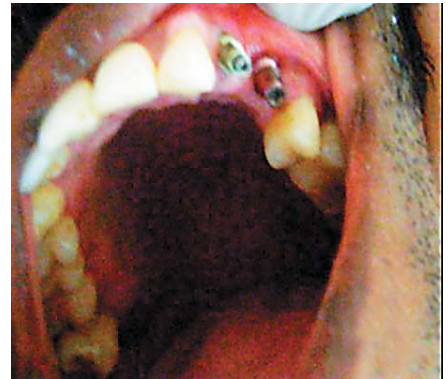

Figure 5: Abutment placement 23, 24 at 7 1/2 month

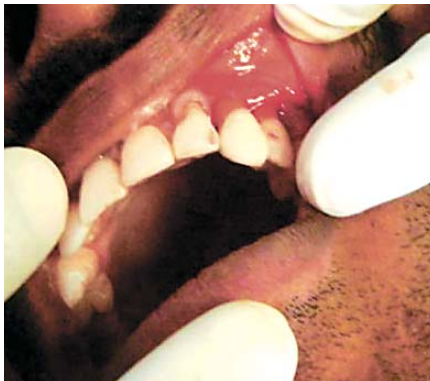

Figure 6: Insertion of crowns in 23, 24 regions.

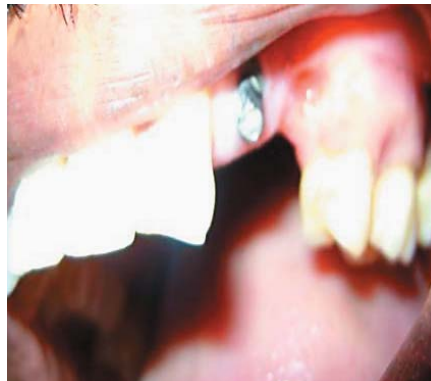

Figure 7: Crown loosening seen in relation to 24 at 8 1/2 month recall.

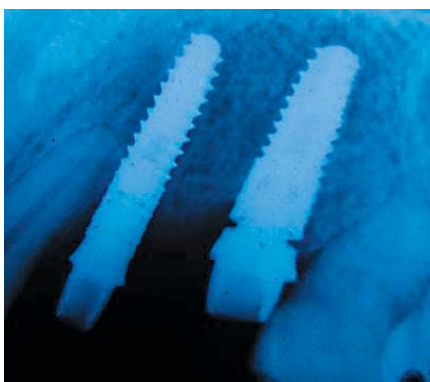
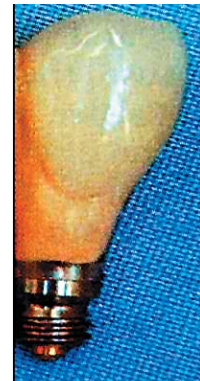

Figure 8: IOPA x-ray revealing microgap between Abutment & Implant of 24

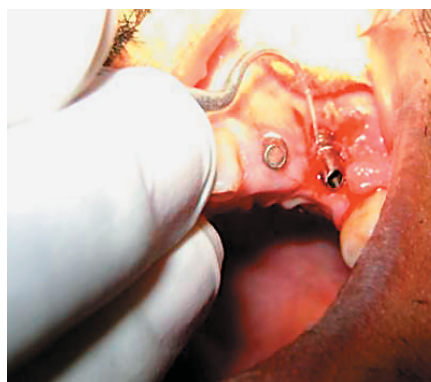

Figure 9: Microgap between Abutment & Implant of 24 detected clinically.

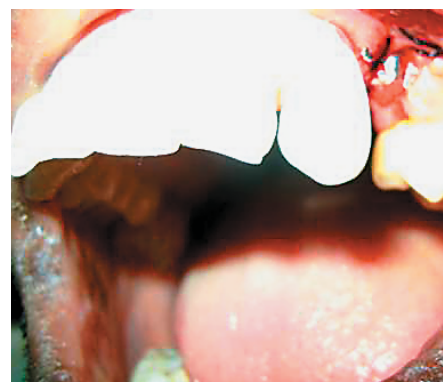

Figure 10: Recall for new abutment in 24 region