INDIAN JOURNAL OF DENTAL ADVANCEMENTS

Journal homepage: www. nacd. in

CASE REPORT

Quick Response Code

doi: 10.5866/3.4.711

A Localized Gingival Enlargement as Peripheral Ossifying Fibroma

Gita Malathi K[1], Ravichandra PV[2], Suresh KumarK[3]

Senior Lecturer[1]
Department of Periodontics
SVS Institute of Dental Sciences
Mahabubnagar - 509002. AP

Professor and HOD[2]
Department of Conservative Dentistry
Kamineni Institute of Dental Sciences
Narketpally, Nalgonda Dist. A.P.

Professor and HOD[3]
Department of Periodontics
Rama Dental College, Kanpur, U.P.

Article Info
Received: July 16, 2011
Review Completed: August, 19, 2011
Accepted: September, 20, 2011
Available Online: January, 2012
© **NAD, 2011** - All rights reserved

ABSTRACT:

Peripheral ossifying fibroma, a oral pathologic condition that appears in the mouth as an overgrowth of gingival tissue is a relatively common lesion accounting for upto 15% of all biopsy gingival lesions. A 24-year-old female patient presented with the chief complaint of a painless swelling in the upper maxillary area of 1 year duration. Clinical examination revealed gingival enlargement localized between upper central and lateral incisors. Excisional biopsy of the gingival lesion and the specimen were submitted for histopathological analysis. Biopsy of the gingival lesion revealed Stratified Squamous Epithelium & highly cellular fibroblastic component presenting central areas of calcification and features consistent with a diagnosis of POF. After 1 year follow up, no recurrence has been observed. Clinician awareness regarding the possibility of such a presentation and its implication will help to ensure optimal treatment outcome.

Key words: ***peripheral ossifying fibroma, oral cavity, Biopsy, peripheral cementifying fibroma, fibrous epulis, calcifying fibroblastic granuloma***

INTRODUCTION

Peripheral ossifying fibroma (POF) is a reactive gingival nodule composed of a cellular fibroblastic connective tissue stroma associated with the formation of randomly dispersed foci of mineralized product consisting of bone, cementum-like tissue, or dystrophic calcification.[1] It is widely considered that this non-neoplastic enlargement of the gingiva originates from the cells of the periodontal ligament[2] and is often associated with trauma or local irritants. Some authors have called it fibrous epulis, calcifying fibroblastic granuloma, or peripheral fibroma with calcification.

Peripheral ossifying fibroma presents as a painless, hemorrhagic and often lobulated mass of the gingiva or alveolar mucosa sometimes presenting with large areas of surface ulceration. Most lesions are 1-2 cm in size, but some may slowly enlarge to more than 4 cm.

The POF may occur at any age range,[3] especially in individuals with poor oral hygiene; but the lesion exhibits a peak incidence between the second and third decades with females being affected more than males.[4] The maxillary gingiva is involved more often than the mandibular gingival with a predisposition towards the anterior regions.[5] Mobility and/or migration of adjacent teeth are occasionally observed. However, on rare occasions, superficial erosion of bone can be seen. The lesions should be surgically excised and submitted for microscopic examination for confirmation of diagnosis.

CASE REPORT

A 24 year- old female patient visited the Department of Periodontics, presenting an exophytic mass in oral cavity that had enlarged gradually for 6

Email for correspondence:
gitamalathi@yahoo.co.in

months. Clinical examination revealed gingival enlargement, measuring 3x2 cm in diameter localized between upper central and lateral incisors with a pedunculated, non-tender and light pinkish mass in the upper anterior maxillary area (Figures 1&2).

The lesion was asymptomatic, non-ulcerated, and the overlying mucosa showed no abnormal changes. Radiographs of OPG and IOPA X-rays were taken in relation to upper central incisors. No radiological signs of involvement of alveolar ridge were observed on the roentgenogram (Figure 3).

TREATMENT

Under local anaesthesia, the lesion was completely excised using electrocautery (Figure 4).The excised tissue measured 3x2 cm (Figure 5).The resultant area was debrided (figure 6) and a COE pack was placed. (Figure 7) The excisional biopsy was submitted for histological analysis. The histopathological examination (Figure 8) of the lesion revealed the prominent area of highly cellular fibrous connective tissue showing collagen fibers and proliferating plump fibroblasts, and focal areas of trabecular bone lined by osteoblasts. The covering stratified squamous epithelium was parakeratinized with focal areas of acanthosis. The diagnosis established according to both clinical and histopathological patterns was that of POF.

DISCUSSION

Ossifying fibroma occurs mostly in craniofacial bones and is generally categorized into two types, central and POF. The central type arises from the endosteum or the periodontal ligament (PDL) adjacent to the root apex and expands from the medullary cavity of the bone. On the other hand, the peripheral type shows a contiguous relationship with the PDL, occurring solely on the soft tissues overlying the alveolar process. In spite of confusing terminology, POF is not the peripheral counterpart of the central ossifying fibroma of the mandible and maxilla,[6] but instead is a reactive gingival lesion known under the generic name of epulis.

The etiology of POF is unclear. Trauma or local irritation such as dental plaque, calculus, ill-fitting dental appliances and poor-quality dental restorations are all known to precipitate the development of POF. Inflammatory hyperplasia originating in the superficial PDL is considered to be a factor in the histogenesis of the POF. Furthermore, a high female predilection, rare occurrence in the first decade, and decline in incidence after age 30 suggest that hormonal influence may be a lesional growth factor.[7]

Clinically, the POF presents as an exophytic, smooth-surfaced, pink or red nodular mass that is sessile, or is less frequently seen on a pedicle. The interdental gingival papilla is frequently involved.[8] In general, the pyogenic granuloma presents as a soft, friable nodule that bleeds with minimal manipulation, but tooth displacement and resorption of alveolar bone are not observed. Although peripheral giant cell granuloma has clinical features similar to those of POF, the latter lacks the purple or blue discoloration commonly associated with peripheral giant cell granuloma and radiographically shows small flecks of calcification. Thus, the diagnosis of the POF based only on clinical aspects can be difficult and histopathological examination of the surgical specimen obtained by excisional biopsy is mandatory for an accurate diagnosis. In the case reported, the histopathological feature of the POF is characterized by the presence of connective tissue with high cellularity and calcifications.[9]

Peripheral ossifying fibromas appear microscopically as a combination of a mineralized product and fibrous proliferation. Usually fibrous proliferation is accompanied by increased cellularity with plump, immature fibroblasts and variable amounts of calcified material.[10] The mineralized portion may be osteoid, cementoid, or dystrophic. In some cases, this characteristic pattern is only part of the pattern of a larger lesion that may resemble an irritation fibroma or pyogenic granuloma or fibroma has existed for a longer period of time.

The differential diagnosis for oral cavity tumors in the pediatric age group includes haemangioma, lymphangioma, salivary gland tumors from the hard palate and pyogenic granuloma from the gingiva. POFs can be clinically misdiagnosed as a pyogenic granuloma at an early stage.[11] Pyogenic granulomata are highly vascular non-tumourous conditions involving gingival tissues, with a tendency to

haemorrhage. Pyogenic granulomas are usually very small (from a few millimetres to 1 cm) and only occasionally show calcification However, some researchers believe that POF is related to pyogenic granuloma and is probably a matured pyogenic granuloma containing fibrosis and calcification.[9]

Treatment consists of excision down to the periosteum and the elimination of any local irritants. Care must be taken to maintain or reestablish acceptable gingival architecture and periodontal integrity. Even in cases complicated by recurrence, re- excision is generally successful, with the retention of the associated teeth.[10] The recurrence rate of POF is high for a benign, reactive growth, varying from 7% to 45%.[12] Thus, total excision is the preferred management of POF.

CONCLUSION

In conclusion, a slowly growing soft tissue mass with speckled calcifications in the anterior oral cavity of children or young adults should raise the suspicion of a reactive gingival lesion such as POF.

REFERENCES

1. Neville BW, Damm DD, Allen CM, Bouquot JE. Oral and maxillofacial pathology.Philadelphiavol1: Saunders; 1995. p. 374-376.
2. Mesquita RA, Sousa SC, Araujo NS. Proliferative activity in peripheral ossifying fibroma and ossifying fibroma. J Oral Pathol Med 1998; **27**:64-67.
3. Eversole LR, Rovin S. Reactive lesions of the gingival. J Oral Pathol 1972;**1**:30-38
4. Kahn, MichaelA.http://en.wikipedia.org/Peripheral_ossifying_fibroma.Pathology|Dentistry
5. Buchner A. Peripheral odontogenic fibroma. J Cranio Max Facial Surg 1989; **17**: 134-138.
6. Miller CS, Henry RG, Damm DD. Proliferative mass found in the gingiva. J Am Dent Assoc 1990;**121**:559-560
7. W-J Moon*, 1, SY Choi2, EC Chung2, KH Kwon3 and SW Chae. Peripheral ossifying fibroma in the oral cavity: CT and MR findings Dento maxillofacial Radiology 2007;**36**:180-182.
8. UM Das, UAzher., Peripheral ossifying fibroma Journal of Indian society of pedodontics and preventive dentistry 2009**;27**: 49-51.
9. Buchner A, Hansen LS. The histomorphologic spectrum of peripheral ossifying fibroma. Oral Surg Oral Med Oral Pathol 1987; **63**:452-461.
10. Kendrick F, Waggoner WF. Managing a peripheral ossifying fibroma. J Dent Child 1996; **63**: 135-138.
11. Cuisia ZE, Brannon RB. Peripheral ossifying fibroma–a clinical evaluation of 134 pediatric cases. Pediatric Dent 2001; **23**: 245-248.

Figure 1. Patient with Peripheral Ossifying fibroma(POF)

Figure 2. Lateral view-POF

Figure 3. IOPA X-ray 11, 21

Figure 4. Excision with electrocautery using Loop electrode.

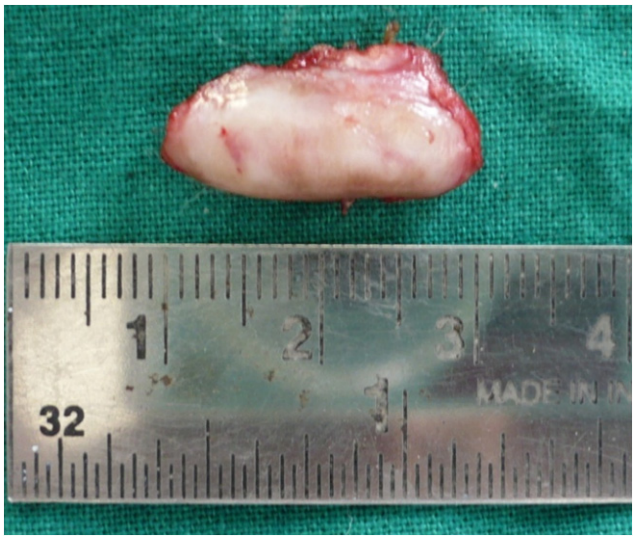

Figure 5. Excised tissue measuring 3x2 cm.

Figure 6. Immediate post operative view

Figure 7. COE pack placed

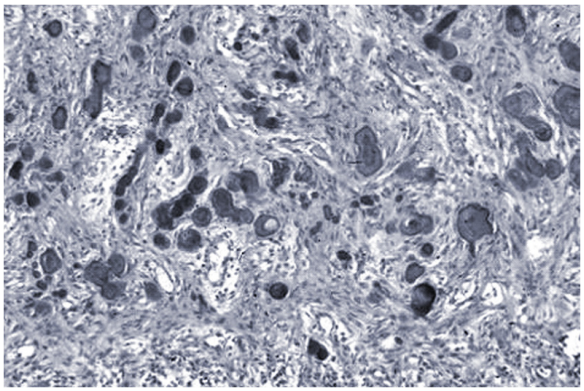

Figure 8. Histopathological slide of the excised specimen

Figure 9. 3-months post-op view