

CASE REPORT

Quick Response Code



doi: 10.5866/4.1.779

Management of myofascial pain dysfunction syndrome

Maj Priyanka Prakash¹, Col Rath SK², Lt Col Mukherjee M³

Division of Periodontology,
Department of Dental Surgery,
AFMC, Pune.

PG Resident¹
Associate Professor^{2&3}

Article Info

Received: January 17, 2012

Review Completed: February, 18, 2012

Accepted: March 20, 2012

Available Online: April, 2012

© NAD, 2012 - All rights reserved

ABSTRACT:

Myofascial pain dysfunction syndrome is a painful condition arising from trigger points in a muscle that occur due to the facial muscles going into spasm. There are numerous precipitating factors that could lead to the causation of myofascial pain dysfunction syndrome and if undiagnosed or left untreated could lead to chronic pain and loss of function. The aim of this case report is to highlight the management of the symptoms of myofascial pain dysfunction syndrome and to regain and maintain normal function with as much independence as possible. The treatment plan included the construction of a relaxation splint with an aim of disoccluding the posterior teeth. A flat plane appliance for arch stabilization was constructed over the maxillary anterior teeth. The relaxation appliance fabricated for the patient in this case helped in reducing the activity of masticatory muscles and reduce parafunctional habits.

Key words: *Myofascial pain dysfunction syndrome, trigger points, relaxation splint.*

Introduction

Myofascial pain dysfunction syndrome (MPDS) is a painful condition in which distinct trigger point areas, generally within muscles or fasciae, become abnormally active and produce local and referred pain. The traditional and narrow definition of myofascial pain is that it is a pain that arises from trigger points (TRPs) in a muscle.¹

One of the most characteristic features of MPDS is the presence of trigger points which are small and sensitive areas in a muscle that spontaneously or upon compression cause pain to a distant region,

known as the referred pain zone. Taut bands (TBs) are groups of muscle fibres that are hard and painful on palpation and constitute an objective and consistent palpatory finding in muscles with myofascial pain. The muscles are in spasm, with increased tension and decreased flexibility [2].

Precipitating and perpetuating factors such as macrotrauma including contusions, sprains and strains may give rise to MPDS acutely but in case of microtrauma the onset is more subtle. Chronic repetitive overloading or overuse of muscles may lead to fatigue, nutritional deficiencies, vitamin or mineral insufficiencies and chronic viral and parasitic infections may perpetuate MPDS.

Email for correspondence:
priyankaprakash58@rediffmail.com

The aim of this case report is to highlight the management of the symptoms of MPDS and to regain and maintain normal function with as much independence as possible

Cases of MPDS if left untreated, may become an irritative focus and send persistent pain impulses via a sensory neuron into the spinal cord. The spinal loop that is constantly bombarded with noxious stimuli and irritated may develop the facilitated release of nociceptive neurotransmitters.

Case Report

A twenty nine year old female patient reported to the Dept of Dental Surgery with a chief complaint of pain with respect to both sides of face and neck for past one year. She is a house wife and first experienced pain with relation to sides of face a year ago. The pain radiated to the sides of the temples, pre and post auricular area, jaws, neck and shoulders. The pain aggravated on chewing food and was associated with frequent headache. Her medical history revealed that she had visited many hospitals & undergone many investigations for the relief of the pain which she suffered. She had been treated for migraine and trigeminal neuralgia after consultation with a neurologist. Her investigations included magnetic resonance imaging (MRI) brain (Normal unenhanced MR Scan of brain) and 2-D Echo scan (Normal study report) and the patient was put on Tab Pregalin (gamma aminobutyric acid analogue for neuropathic pain) 75mg bid, Tab Ketoral (Ketorolac) 10 mg bid each for 5 days, Tab Dolo (Paracetamol) 650 mg bid and Tab Nuloc (Esmoprazol) 20 mg od for 5 days. She had also undergone physiotherapy and Transcutaneous Electric Nerve Stimulation (TENS) therapy without any significant relief. The patient was advised by an ENT specialist to take steam inhalation & antihistamines. She also gave a history of no deleterious oral habits.

On intraoral examination it was observed she had a normal class I occlusion with a full complement of teeth. She had no restorations and no decay in any of her teeth. The patient complains of clicking on opening the temporomandibular joint (TMJ) and on palpation revealed tenderness pre-auricularly. She had a normal mouth opening. She also had tenderness on palpation of the body of the mandible, side of the head, anterior cervical aspect and posterior lateral aspect of neck. Her routine blood investigations were within normal limits and the orthopantomogram revealed no anomaly of TMJ [Fig.1]. There was no erosion of the head of the condyle characteristic of rheumatoid arthritis and no osteophytes were visible.

A RF factor test was done to rule out rheumatoid arthritis and a diagnosis of Myofascial pain dysfunction syndrome was arrived at.

A treatment plan was formulated which included the impression of the maxillary and mandibular arches. A bite was recorded using a wax template by asking the patient to bring the mandible forward and allowing the posterior teeth to disocclude [Fig.2]. A flat plane appliance for arch stabilization was constructed over the maxillary anterior teeth with the aim of disoccluding the teeth and relaxing the musculature [Fig.3&4]. The patient was advised to wear the appliance 24 hours a day and remove it only while eating food [Fig.5&6]. She was asked to take soft diet perform certain muscle relaxation exercises. The patient reported four months later with complete relief of muscle tenderness and pain in the region of TMJ.

Discussion

Musculoskeletal pain is a major cause of morbidity.² It is more prevalent in women and increases with age. A growing number of individuals

have musculoskeletal pain that affects their daily activities and function and has a significant impact on their quality of life causing a financial burden on our healthcare system.³ Muscles in general, and myofascial pain in particular, have received less attention as a major source of pain and dysfunction.

Precipitating factors of MPDS may cause the facilitated release of acetylcholine at motor end plates, sustained muscle fibre contractions, local ischaemia with release of vascular and neuroactive substances, and muscle pain. More acetylcholine may then be released, thus perpetuating the muscle pain and spasm. Electrodiagnostic studies have shown increased electromyographic activities at trigger points and tender spots.^{4,5}

The relaxation appliance fabricated for the patient in this case helped in reducing the activity of masticatory muscles and helped to reduce parafunctional habits.

The main differential diagnosis of MPDS includes neuropathy, bursitis, tendonitis, psychiatric disorders including depression, fibromyalgia and referred visceral pain to name a few.

Myofascial pain, which is a common treatable cause of morbidity, is often under-diagnosed and under-treated. If left undiagnosed and untreated, it may develop into chronic pain with overlying psychosocial and functional problems. This may lead to further distress, anxiety and even depression. The vicious cycle may give rise to further somatic preoccupation. This major source of musculoskeletal dysfunction requires more focused attention. Its early diagnosis and treatment may help to reduce overlying psychosocial complications and the attending financial burden of chronic pain syndrome.

A large number of patients can be left suffering in pain for years. Once diagnosed MPDS can be completely cured with limited rate of recurrence.^{6,7}

Conclusion

Diagnosing a case of myofascial pain dysfunction syndrome is challenging yet once diagnosed it can be completely cured. The pain arises from trigger points present in the muscles that are in spasm. Construction of a relaxation splint restores the normal functioning of the muscle and provides relief from pain due to relief of the spasm. On a four month follow up the patient had relief from pain however long term follow up is required in order to evaluate the recurrence of symptoms.

Acknowledgements and conflicts of interest - Nil

References

1. Travel JG, Simons DG. Myofascial pain and dysfunction: The trigger point manual vol. 1 and Baltimore: Williams & Wilkins, 1999.
2. Wolfe F, Smythe HA, Yunus MB, Bennett RM, Bombardier C, Goldenberg DL, et al. The American College of Rheumatology 1990 Criteria for Classification of Fibromyalgia. Report of the Multicenter Criteria Committee. *Arthritis Rheum* 1990;**33**: 160-172.
3. World Health Organization: The burden of musculoskeletal conditions at the start of the new millennium: Report of a WHO scientific group. Geneva, Switzerland: WHO, 2003.
4. Association of American Medical Colleges, Report VII, Contemporary Issues in Medicine: Musculoskeletal Medicine Education, Medical School Objectives Project. Washington DC, 2005.
5. Borg-Stein J, Simons DG. Focused review: myofascial pain. *Arch Phys Med Rehabil* 2002;**83** (3 Suppl 1):40-47.
6. Hsueh TC, Yu S, Kuan TS, Hong CZ. Association of active myofascial trigger points and cervical disc lesions. *J Formos Med Assoc* 1998;**97**: 174-180.
7. Fernandez-de-Las-Penas C, Arendt-Nielsen L. Sympathetic facilitation of hyperalgesia evoked from myofascial tender and trigger points in patients with unilateral shoulder pain. *Clin Neurophysiol* 2006;**117**:1545-1550.

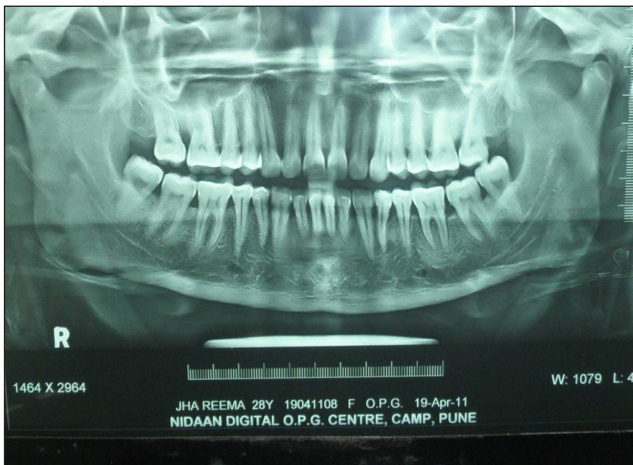


Figure 1 - Fabrication on a cast



Figure 2 - The bite recorded

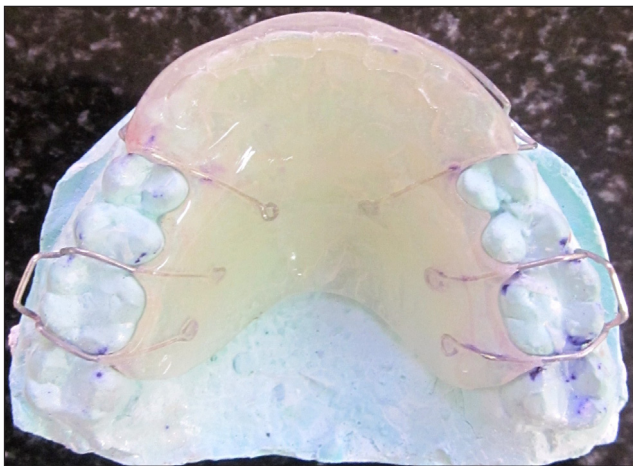

Figure 3 - The relaxation splint

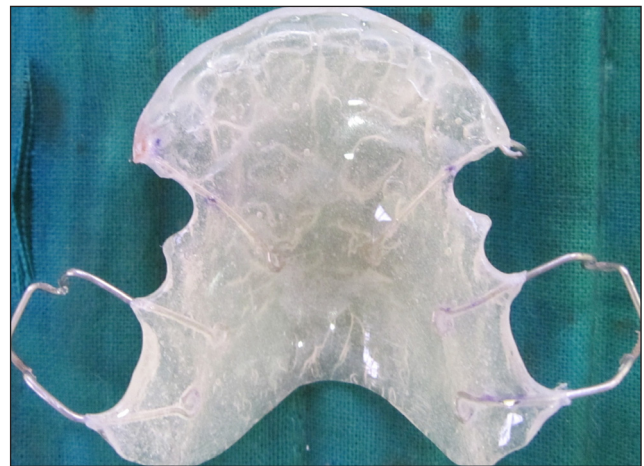


Figure 4 - Patient wearing relaxation splint in occlusion

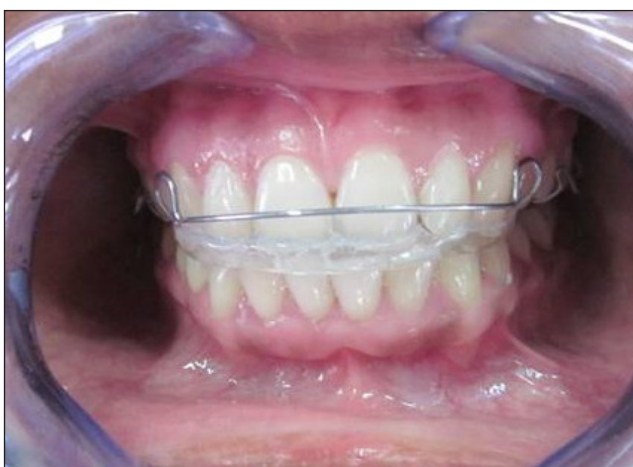

Figure 5 - Relaxation splint fit on maxillary teeth

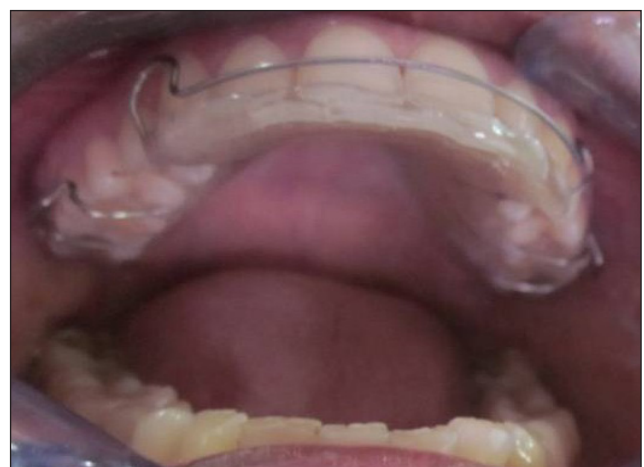

Figure 6 - A normal orthopantomogram with no evidence of pathology.