Endodontic Management of Hypertaurodontism

Saritha Vallabhaneni[1], Radhakrishna Gogineni[2], Ganesh More[3]

Quick Response Code

doi: 10.5866/4.4.1002

[1]Profesor
[3]PG Student
Dept. of Conservative Dentistry
PMNM Dental College
Rajiv Gandhi Health University

[2]Professor,
PG GUIDE, Dept. of Orthodontics
PMNM Dental College
Rajiv Gandhi Health University

Article Info:
Received: July 16, 2012;
Review Completed: August 15, 2012;
Accepted: September 13, 2012
Available Online: January, 2013 (www.nacd.in)

Email for correspondence:
sarithavallabhaneni@yahoo.com

ABSTRACT:

Taurodontism is a morphoanatomical change in the shape of a tooth, which usually occurs in multirooted teeth. An enlarged body and pulp chamber, as well as apical displacement of the pulpal floor, are characteristic features. Endodontic treatment of a taurodont tooth is challenging, because it requires special care in handling and identifying the number of root canals. A case of endodontic treatment of a maxillary first molar with hypertaurodontism not associated with any syndrome is presented.

Key words: Hypertaurodontism, Enlarged pulp chamber, Taurodontism, Hertwig's epithelial root sheath (HERS), Bull teeth

INTRODUCTION

Taurodontism is a developmental anomaly in tooth morphology characterised by the lack of constriction at the level of the cementoenamel junction, vertically elongated pulp chambers and apical displacement of the pulpal floor.[1] The term Taurodontism is derived from the Latin - tauros, for 'bull' and the Greek term odus, for 'tooth'; or 'bull tooth', first introduced by Sir Arthur Keith in 1913[2] Taurodonts have pulp chambers in which the bifurcation or trifurcation is displaced apically, so the distance from the bifurcation or trifurcation of the roots to the cementoenamel junction is greater than the occlusalcervical distance, giving it a rectangular shape.[3]

The etiology of taurodontism is unclear. It is thought to be caused by the failure of Hertwig's epithelial sheath diaphragm to invaginate at the proper horizontal level or changes in the mitotic activity of cells

of the developing teeth that can affect root formation[4] or influence from external factors on the development of the teeth[5] resulting in a tooth with short roots, elongated body, an enlarged pulp, and normal dentin[6] Previously, taurodontism was related to syndromes such as Down's and Klinefelter's syndrom.[7] Today, it is considered as an anatomic variance that could occur in a normal population[8]

The prevalence is reported to range from 2.5% to 11.3% of the population.[9,10] Taurodontism may be unilateral or bilateral with no sex predilection and affects permanent teeth more frequently than primary teeth. Mandibular molars are found to be affected more often than maxillary molars and the mandibular second molar is the most frequently involved tooth.

In the oral cavity, a taurodont appears as a normal tooth. The diagnosis of taurodontism is usually made from diagnostic radiographs. The severity of taurodontism is classified according to degree of apical displacement of the pulpal floor[11] Least pronounced (hypotaurodontism), moderate (mesotaurodontism), and most severe (hypertaurodontism). Shifman and Chanannel[12] proposed an index to calculate the degree of taurodontism as shown radiographically. According to this index, taurodontism is present if the distance from the lowest point at the occlusal end of the pulp chamber to the highest point at the apical end of the chamber, divided by the distance from the occlusal end of the pulp chamber to the apex and multiplied by 100 is 20 or above (hypotaurodontism TI 20-30, mesotaurodontism TI 30-40 and hypertaurodontism TI 40-75).

Taurodontism, although not common, is an important occurrence that may influence dental management of patients. The present case describes endodontic treatment of a maxillary first molar with rare hypertaurodontism in a healthy individual with no associated syndrome or anomaly.

Case report

A 26-year-old patient reported to the Department of Conservative Dentistry and Endodontics, P M N M Dental College, Bagalkot, with pain on biting on the upper right back tooth for 1 month, The tooth had an exaggerated response to heat with lingering pain. Medical and family histories were non-contributory. On intraoral examination, there was a deep mesio-proximal carious lesion in the maxillary right first molar (tooth 16) and disto-proximal carious lesion in the second premolar (tooth 15). The tooth was sensitive to percussion suggestive of symptomatic apical periodontitis. An intraoral periapical (IOPA) radiograph of maxillary right first molar (tooth 16) revealed the presence of a coronal radiolucency involving the pulp chamber and widening of the apical periodontal ligament space confirming the diagnosis of symptomatic apical periodontitis with elongated pulp chamber which divides at the apical 3rd, indicating hypertaurodontism according to Shifman and Chanannel[12] (Fig. 2). Hypertaurodontism on the contralateral side was confirmed by OPG (Fig. 1). Root canal therapy was advised for tooth 46. The tooth was anaesthetised. Magnification loops (STAC, A product of ACTS Medical Mississauge, Canada) were used throughout the procedure to facilitate visualization. The tooth was isolated and the access cavity prepared. The tooth was instrumented to the furcation area where three canal orifices which was in the apical 3rd were found: a wide palatal one (P), and two narrow orifices–a mesiobuccal (MB) and a distobuccal (DB). Instrumentation was carried out using a standardised technique with Ni-Ti K-files (Dentsply Maillefer, Ballaigues, Switzerland). An electronic apex locator (Root ZX; Morita, Tokyo, Japan) was used to determine the initial working length. and working length was confirmed with radiograph(Fig. 3), The palatal canal was instrumented to #40 file and the buccal canals to a #35 file size. Sodium hypochlorite 3%(Venson, India) and 2% chlorehexidine(V-Consept, Dentocare PVT LTD, Sarkej, Ahmedabad, Gujrat,

India) were used as irrigating solutions. A modified obturation technique was used because of the complexity of the inner root canal anatomy and the proximity of the buccal orifices. This consisted of combined lateral condensation of the individual canals followed by vertical compaction of the elongated pulp chamber, using the obtura II (LPS laboratories, Tucker, GA, USA). AH Plus sealer(Densply, Konstanz, Germany) was used The final radiograph confirmed a well-condensed filling consisting of three canals obturated to the predetermined length (Fig. 4). Postobturation filling done with amalgam followed by crown.

Discussion

Taurodontism is frequently associated with other anomalies and syndromes.[13] Clinically, the taurodont crown has normal form, structure, colour and texture, so, it can only be diagnosed by radiographs. Taurodontism is predominantly found in the molars but has also been seen in premolars, mandibular canines and incisors.[1,14] In the present case, the patient was a healthy male with no known diseases, mandibular first and second molars have shown taurodontism. In this case all the types of taurodontism are present, hypo (all second molars), meso (lower first molar) and hyper (upper first molar), which were diagnosed radiographically and confirmed by using taurodontism index proposed by Shifman and Chanannel.[12] Often taurodont form does not interfere with operative procedures; however, endodontic therapy may be more difficult because of its morphology. The long rectangular shape of pulp chamber seems to cause difficulty in locating the canal orifices and subsequent difficulties in instrumentation and obturation.

The present case describes successful completion of endodontic treatment of a taurodont maxillary first molar, which seemed impossible to perform with conventional techniques. Success was mostly attributed to the use of magnification, which easily showed the location of the three canal orifices. Unfortunately, the patient was unavailable for future followups. To the best of our knowledge, no long-term follow up studies have been published regarding taurodont endodontically treated teeth.

REFERENCES

1. Jafarzadeh H, Azarpazhooh A, Mayhall JT. Taurodontism: a review of the condition and endodontic treatment challenges. Int Endod J 2008; **41**: 375-388..
2. Keith A. Problems relating to the teeth of the earlier forms of prehistoric man. J R Soc Med 1913; **6**: 103-124.
3. Jaspers MT, Witkop CJ Jr. Taurodontism, an isolated trait associated with syndromes and X-chromosomal aneuploidy. Am J Hum Genet 1980; **32**: 396-413.
4. Varrela J, Alvesalo L. Taurodontism in 47, XXY males: an effect of the extra X chromosome on root development. J Dent Res 1988; **67**: 501-502.
5. Reichart P, Quast U. Mandibular infection as a possible aetiological factor in taurodontism. J Dent 1975; **3**: 198-202.
6. Hamner JE, Witkop CJ, Metro PS. Taurodontism. Report of a case. Oral Surg Oral Med Oral Pathol 1964;**18**:409-418.
7. Regezi JA, Scuibba JJ. Oral pathology: clinical pathologic correlations. WB Saunders Company, 1999:458.
8. Shifman A, Chanannel I. Prevalence of taurodontism found in radiographic dental examination of 1200 young adult Israeli patients. Community Dent Oral Epidemiol 1978;**6**:200-2003.
9. Joseph M. Endodontic treatment in three taurodontic teeth associated with 48, XX XY Klinefelter syndrome: a review and case report. Oral Surg Oral Med Oral Pathol Oral Radiol Endod 2008; **105**: 670-677.
10. Sert S, Bayirli G. Taurodontism in six molars: a case report. J Endod 2004; **30**: 601-602.
11. Shaw JC. Taurodont teeth in South African races. J Anat 1928;**62**:476-498.:
12. Shifman A, Chanannel I. Prevalence of taurodontism found in radiographic dental examination of 1200 young adult Israeli patients. Community Dent Oral Epidemiol 1978;**6**:200-2003.
13. Cichon JC, Pack RS. Taurodontism: review of literature and report of case. J Am Dent Assoc 1985; **111**: 453-455.
14. Bharti R, Chandra A, Tikku AP, Wadhwani KK. 'Taurodontism' an endodontic challenge: a case report. J Oral Sci 2009; **51**: 471-474.

Figure 1 : Preoperative OPG

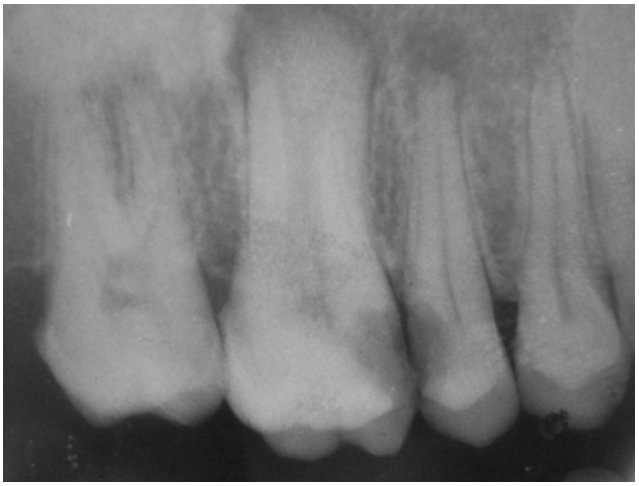

Figure 2 : Preoperative IOPA

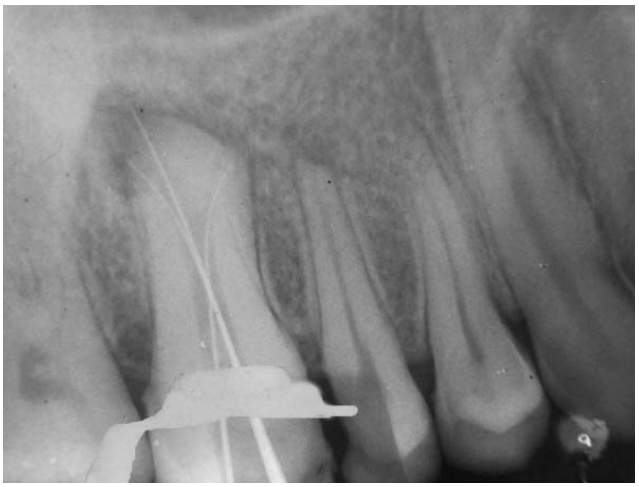

Figure 3 : Working Length IOPA

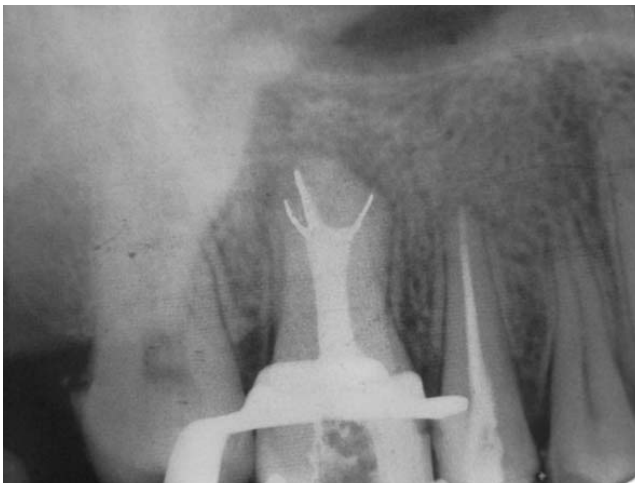

Figure 4 : Postobturation IOPA