CASE REPORT

Presurgical Nasoalveolar Molding in Unilateral Cleft Lip and Palate Patient

Maj Parvinder Sharma[1], Brig HS Sandhu[2], Maj Anil Kumar[3]

Quick Response Code

doi: 10.5866/4.4.1024

[1&3]Graded Specialist
Dept of Prosthodontics, Army Dental Corps, India

[2]Commandant and Command Dental advisor
(Northern Command),
Army Dental Corps, India

Article Info:
Received: July 14, 2012;
Review Completed: August 12, 2012;
Accepted: September 12, 2012
Available Online: January, 2013 (www.nacd.in)

Email for correspondence:
sharmaparvinder@yahoo.co.in

ABSTRACT:
Cleft lip and palate is a common congenital anomaly of the stomatognathic system. Cleft lip and palate can present with considerable variation in severity and form. These clefts, deficient in hard and soft tissue elements present a significant challenge to achieve a functional and cosmetic outcome. So it is desirable to reduce the cleft deformity prior to the surgery for optimal results. The presurgical nasoalveolar technique is a novel procedure which can be used in cleft cases to reduce the cleft deformity presurgically. The goals of presurgical nasoalveolar molding include lip segments that are almost in contact at rest, symmetrical lower lateral alar cartilages, reduction in the width of the alveolar cleft segments until passive contact of the gingival tissues is achieved. In the following case report the pre-surgical nasoalveolar molding technique was used in unilateral cleft lip and palate patient to reduce the cleft deformity prior to surgery. Improved alignment of cleft segments and nasal cartilage was achieved requiring less extensive surgery with good esthetic outcome.

Key words: Cleft lip, Cleft palate, Nasoalveolar Molding

Introduction

Cleft lip and palate is a common congenital anomaly of orofacial region. The incidence of cleft lip and palate in India is 1 in 781 live births [1]. A basic treatment objective for the cleft lip, alveolus and palate patient is to restore normal anatomy. Because of the major hard and soft tissue abnormalities observed in these patients it is highly desirable to restore the correct skeletal, cartilaginous and soft tissue relationship presurgically.

In the following case report the presurgical nasoalveolar molding technique was used in a unilateral cleft lip and palate case. An acrylic molding plate with nasal stent was used in this case for the aligning of cleft segments and molding of nose into desirable form presurgically. The technique takes the advantage of

the malleability of immature cartilage and its ability to maintain a permanent correction of its form.

Case Report

A 20 days old female child with congenital orofacial defect was referred to our institution for evaluation. History revealed that the defect was first observed by her parents at the time of birth. Parents reported to the hospital when the child was 20 days old. General physical examination revealed that the child was of normal weight, moderately built and the vital parameters were under normal range.

On extraoral examination, the patient was noted to have cleft lip left side; columella deviated toward noncleft side; depressed left lateral alar cartilage [Fig. 1]. Intraoral examination revealed complete unilateral cleft involving alveolus, hard palate and soft palate of left side [Fig. 2]. Width of the alveolar gap and palatal gap were measured on the study cast. Nasal parameters were measured directly using thread, sliding calliper, protractor and scale. The various measurements were noted at initial visit [Table 1, 2].

Table 1

Parameter	Measurement
Width of alveolar gap	8 mm
Width of palatal gap	11.2 mm

Width of alveolar gap- Distance between alveolar cleft borders.

Width of palatal gap- Distance between cleft borders in the midst of hard palate.

Table 2

Parameter	Measurement	
Nostril height	Cleft side 1.8 mm	Non cleft side 5.2 mm
Nostril width	Cleft side 12.6 mm	Non cleft side 8.7 mm
Columellar height	Cleft side 5.1 mm	Non cleft side 8 mm
Angle of columella from cleft side	52 degrees	

These measurements were referenced to a horizontal reference line

Reference line- Imaginary line connecting the left and right alar bases

Nostril height - Vertical distance between the horizontal reference line and highest point on alar rim

Nostril width - Distance between alar base and columellar base

Columellar height - The vertical distance between the most inferio- medial and suprerio- medial point along the inner medial surface of nasal aperture

Angle of columella from cleft side - Angle between a line bisecting the columella and horizontal reference line measured on cleft side

The case was discussed with the cleft lip and palate team of our institution and nasoalveolar molding followed by surgery was planned for the child. Presurgical nasoalveolar molding was planned to reduce the cleft deformity prior to the surgery in the department of prosthodontics.

Procedure

The nasoalveolar molding protocol was divided into two phases. In the first phase aligning of the cleft lip, alveolus and palate segments was planned using acrylic molding plate and lip taping. In the second phase correction of the nasal deformity was planned by incorporating nasal stent to the molding plate. The nasal molding phase must follow alveolar molding so as to avoid undue stretching of the alar rim circumference on cleft side.[2]

Impression of the intraoral defect was made using specially fabricated acrylic tray and elastomeric impression material (Soft putty/ regular set- Aquasil, Dentsply) [Fig. 3]. The impression was made with the infant fully awake and without any anaesthesia. The infant was held upside down to prevent the possible aspiration of any regurgitated stomach contents. Two casts were fabricated using dental stone, one for the patent's records and other for the fabrication of molding plate [Fig. 4]. A molding plate was fabricated using clear heat activated methyl methacrylate resin on the working

cast. A retentive button was fabricated using chemically activated methyl methacrylate resin. The retentive button was attached to the molding plate at an angle of 45 degrees [Fig. 5]. The plate was checked in patient's mouth. Adhesive base tapes (Romo Drape-Romsons) of dimension (1.0 X 1.5 inch) were applied to the infant's cheek lateral and superior to the commissures. Small orthodontic elastics (0.25 inch diameter) were incorporated into the loops of Steri Strips (0.25 X 4 inch). The elastic band was placed over the retentive button, and the Steri Strip was pulled and secured to the base tape on the infant's cheek. The lip taping was performed using Steri Strips to align the lip segments and the base of nose [Figure 6]. The plate was activated by selective removal of acrylic from the region where the movement of bone was desired, at the same time soft denture liner (GC Tokyo) was added in the region where bone is required to be moved to close the defect. The patient was evaluated at weekly interval and the appliance was activated as per requirement. After four weeks a nasal stent was fabricated using 0.036 inch stainless steel wire. Acrylic was added to the end of wire to provide support and shape to the nasal dome. The nasal stent was incorporated into the molding plate [Figure 7]. The incorporation of nasal stent is recommended once the alveolar defect size has been reduced to 6 mm or less. The proper sequence of molding (alveolar followed by nasal) was followed to avoid the production of a "mega-nostril". The palate was adjusted at weekly intervals till the primary surgery. The primary lip and nose surgery was performed when the child was five months old. The nasoalveolar molding procedure may be continued from 3-5 months depending on the severity of cleft deformity.[2] The various parameters were measured measured and analysed at four times during the procedure [Table 3 and 4].

Table 3

Age	20 days (Initial visit)	7 weeks	12 weeks	5 months
Width of alveolar gap	8 mm	5.8 mm	4.9 mm	4.2 mm
Width of palatal gap	11.2 mm	9.8 mm	8.2 mm	6.8 mm

Table 4

Age	20 days (Initial visit)	7 weeks	12 weeks	5 months
Nostril height (Cleft side)	1.8 mm	3.9 mm	5.0 mm	6.6 mm
Nostril height (Non cleft side)	5.2 mm	5.8 mm	6.4 mm	7.2 mm
Nostril width (Cleft side)	12.6 mm	11.4 mm	10.8 mm	10.2 mm
Nostril width (Non Cleft side)	8.7 mm	9.1 mm	9.4 mm	9.6 mm
Columellar height (Cleft side)	5.1 mm	6.0 mm	6.8 mm	7.2 mm
Columellar height (Non cleft side)	8 mm	8.3 mm	8.6 mm	8.8 mm
Angle of columella from cleft side	52 degrees	58 degrees	65 degrees	71 degrees

A marked reduction in the alveolar defect and improved columella and nasal alar cartilage positioning was achieved [Figure 8,9,10,11]

Discussion

There have been numerous techniques documented over the centuries to improve the position of the cleft segments. In 1686, Hoffman described the use of a head cap to retract the premaxilla and narrow the cleft.[3] The concept of an intraoral device to reposition the cleft alveolar segments is attributed to McNeil.[4] In 1975, Georgiade and Latham introduced a pin-retained appliance to simultaneously retract the pre-maxilla and expand the posterior segments.[5] Hotz described the use of a passive orthopedic plate to align the cleft segments.[6] All of these appliances were designed to correct the alveolar cleft only, despite

the fact that the cleft nasal deformity remains the greatest esthetic challenge.

In 1993, Grayson et al described a technique to correct the alignment of alveolus, lip and nose in infants born with cleft lip and palate.[7] The original research for molding cartilage was performed by Matsuo.[8] He recognized that the cartilage in the newborn is soft and lacks elasticity. He stated that the high level of estrogen at the time of birth correlates with the increased hyaluronic acid, which inhibits the linking of the cartilage intercellular matrix.

The principle objective of presurgical nasoalveolar molding is to reduce the severity of the initial cleft deformity. The objectives include lip segments that are almost in contact at rest, symmetrical lower lateral alar cartilages, and adequate nasal mucosal lining, which permits postsurgical retention of the projected nasal tip. Additional objectives of nasoalveolar molding include reduction in the width of the alveolar cleft segments. As reduction of the alveolar gap width is accomplished, the base of the nose and lip segments achieves improved alignment.

The nasoalveolar molding protocol consists of two stages. In the first stage the leveling and aligning of the cleft lip, alveolus and palate segment is planned. After the reduction in the size of alveolar defect the correction of nasal deformity is planned. The appliance is activated weekly. The appliance is worn till the date of primary lip and nose surgery. After the surgery the appliance is discontinued.

The benefits of presurgical nasoalveolar molding are numerous. In the short term, the tissues are well aligned before primary lip and nose repair, which enables the surgeon to achieve a better and predictable outcome with less scar tissue formation. In long term, the change in nasal shape is stable with less scar tissue and better lip and nasal form.[9] This improvement reduces the number of surgical revisions for excessive scar tissues, oronasal fistulas, nasal and labial deformities. With the alveolar segments in better position and increased bony bridges across the cleft, the permanent teeth have a better chance of erupting in appropriate positions. Approximation of the alveolar segments permits the surgeon to perform gingivoperiosteoplasty.

After nasoalveolar molding primary surgical closure of the lip and nose is performed from 3 to 5 months of age.[10] Because the alveolar segments are in approximation a gingivoperiosteoplasty is simple for the surgeon to perform, avoiding excessive dissection.[11,12]

Recently computer- aided reverse engineering and rapid prototyping have been used for the fabrication of digital model, appliance designing and appliance fabrication to simplify the procedure.[13]

Conclusion

Presurgical nasoalveolar molding for a unilateral cleft lip and palate patient has been described in this case report. The objective of this procedure was to reduce the cleft deformity presurgically. The nasoalveolar molding resulted in the reduction of the cleft deformity requiring less extensive surgery with good esthetic outcome. Moreover it is reported in literature that the presurgical molding used to reduce the cleft deformity does not inhibit midface growth.[14,15]

References

1. Raman S, Jacob M, Jacob MS, Nagarajan R. Providing intervention services for communication deficits associated with cleft lip and / or palate - A retrospective analysis. Asia Pacific Disability Rehabilitation Journal 2004;**15**(2):78-85.

2. Thomas D Taylor. Clinical maxillofacial prosthetics. 1st ed. Quintessence publishing company; 2000.

3. Millard DR. Cleft Craft: Bilateral and rare deformities. 1st ed. Boston: Little Brown & company; 1977.

4. McNiel CK. Orthodontic procedures in the treatment of congenital cleft palate. Dental Record 1950;**70**:126-132.

5. Georgiade N, Latham R. Maxillary arch alignment in bilateral cleft lip and palate infant, using pinned coaxial screw appliance. Plast Reconstr Surg 1975;**56**:52-60.

6. Hotz M, Perko M, Gnoinski W. Early orthopaedic stabilization of premaxilla in complete bilateral cleft lip and palate in combination with celenisk lip repair. Scand J Plast Reconstr Surg Hand Surg 1987;**21**:45-51.

7. Grayson BH, Cutting CB, Wood R. Preoperative columella lengthening in bilateral cleft lip and palate. Scand J Plast Reconstr 1993;**92**:1422-1433.

8. Matsuo K, Hirose T, Tomono T, Iwasawa M, Katohda S, Takahashi N, Koh B. Nonsurgical correction of congenital auricular deformities in early neonate; a preliminary report. Plast Reconstr Surg 1984; **73**: 38-51.

9. Maull DJ, Grayson BH, Cutting CB, Brecht LL, Bookstein FL, Khorrambadi D, Webb JA. Long term effects of nasoalveolar molding on three dimensional nasal shape in unilateral clefts. Cleft Palate Craniofac J. 1999;**36**:391-397.

10. Cutting CB, Bardach J, Pang R. A comparative study subsequent to rotation -advancement and triangular flap lip repairs. Plast Reconstr Surg 1989;**84**:409-417.

11. Yagci A, Usyal T. Evaluation of the effect of nasoalveolar molding method on cleft segments and alveolar width of babies with unilateral cleft lip and palate. Journal of Health Sciences 2007;**16**:1-10.

12. Radhakrishnan V, Sabarinath VP, Thombare P, Hazarey PV, Bonde R, Sheorain A. Presurgical nasoalveolar molding assisted primary construction in complete unilateral cleft lip palate infants. Journal of Clinical Pediatric Dentistry 2010;**34**:267-274.

13. Quan Y, Xin G, Guo-Min W, Zhe -Yuan Y, Yu-Fen Q, Gang S. A novel technique for presurgical nasoalveolar molding using computer-aided reverse engineering and rapid prototyping. Journal of craniofacial surgery 2011;**22**:142-146.

14. Wood RJ, Grayson BH, Cutting CB. Gingivoperiosteoplasty and midface growth. Cleft palate J 1997;**34**:17-20.

15. Catherine TH, Grayson BH, Cutting CB, Brecht LE, Lin WY. Prepubertal midface growth in unilateral cleft lip and palate following alveolar molding and Gingivoperiosteoplasty.Cleft palate-Craniofacial Journal 2004; **41**:375-380.

Figure 1: Preoperative extraoral photograph of the patient showing cleft defect

Figure 2: Preoperative intraoral photograph

Figure 3: Impression of the intraoral defect

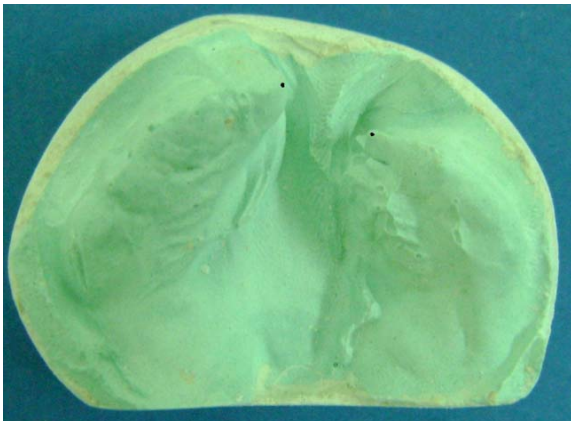

Figure 4: Study cast of intraoral defect

Figure 5: Molding plate with retentive button

Figure 6: Cheek and lip taping

Figure 7: Nasal stent incorporated into molding plate

Figure 8: Study cast prior to primary surgery

Figure 9: Intraoral photograph prior to surgery

Figure 10: Postoperative photograph of the patient

Figure 11: Photograph after 12 months follow up