CBCT in Orthodontics - An Overview

Vasu Murthy Sesham[1], Lalitha Ch[2], Srinivas Baratam[3], Indraneel N[4]

Quick Response Code

doi: 10.5866/4.4.984

[1]Professor & HOD
[2]Senior Lecturer
[4]Post Graduate Student
Department of Orthodontics
Kamineni Institute of Dental Sciences,
Narketapally, A.P.

[3]Professor
Kalinga Institute of Dental Sciences, Bhubaneshwar.

Article Info:
Received: July 10, 2012;
Review Completed: August 13, 2012;
Accepted: September 10, 2012
Available Online: January, 2013 (www.nacd.in)

Email for correspondence:
vasuortho@gmail.com

ABSTRACT:

The long awaited addition of third dimension to our radiographic records is now a reality. Cone beam Computed tomography has become an increasingly important source of 3D data in clinical orthodontics. It was developed due to increasing demand for 3D information obtained by conventional computerized tomography scans. A cone beam examination is recommended in detection of facial asymmetry, assessing shape and growth of mandible, localisation of impacted canines, provides information for the placement of temporary anchorage device, evaluation of root resorption repair, assigning changes in oropharynx in growing patients with maxillary constriction treated with rapid palatal expansion etc.

Key words: Computed tomography, Digital imaging, and Cone beam.

INTRODUCTION

Accurate diagnostic imaging is essential to derive the correct diagnosis and treatment plan, as well as to monitor the treatment progress and final outcome. In the past Two-dimensional (2D) diagnostic imaging, including traditional radiographs, cephalometric tracings, photographs and video imaging, has been a part of the orthodontic patient record. With the limitations of these imaging modalities, which include magnification, geometric distortion, superimposition of structures, projective displacements, and rotational errors. In contrast to 2D, three-dimensional (3D) imaging allows for the evaluation of an anatomical object in three orthogonal planes. Earlier 3D information was confined to plaster and even more recently digital study models, as well as the clinical examination of the patient. But now cone beam CT (CBCT) has increasingly become an important source of 3D data in clinical orthodontics.[1]

IMPORTANT DATES IN ORTHODONTIC IMAGING HISTORY.[2]

- 1931- B. Holly Broadbent invented the cephalometer.
- 1948-William Downs published the first cephalometric analysis.
- 1959-First cephalometric workshop was held at the Bolton Study in Cleveland, Ohio.
- 1981-David Sarver combined 2D digital imaging of the face with digital cephalogram starting the 2D digital age.
- 2001-NewTom introduced the first cone beam scanner for dental use.
  - 3D digital imaging began with the introduction of first CBCT by Joe Caruso in Loma Linda, USA.
- 2008-First meeting of the Joint Cephalometric Expert Group was held at the Bolton Brush Growth Study Centre, Cleveland.

WHAT IS CONE BEAM C.T & HOW DOES IT WORK

Cone beam computed tomography (CBCT) is an image production system which is frequently used in the field of orthodontics. It provides accurate two- and three-dimensional radiographic images of an anatomical structure, in the selected field of view.[3]

Image production is done by using a rotating gantry to which an x-ray source and detector are fixed. A divergent pyramidal or cone-shaped source of ionizing radiation is directed through the middle of the area of interest. The x-ray source and detector rotate around a rotation fulcrum fixed within the centre of the region of interest. During the rotation, multiple (from 150 to more than 600) sequential planar projection images of the field of view (FOV) are acquired in a complete, or sometimes partial arc.[4]

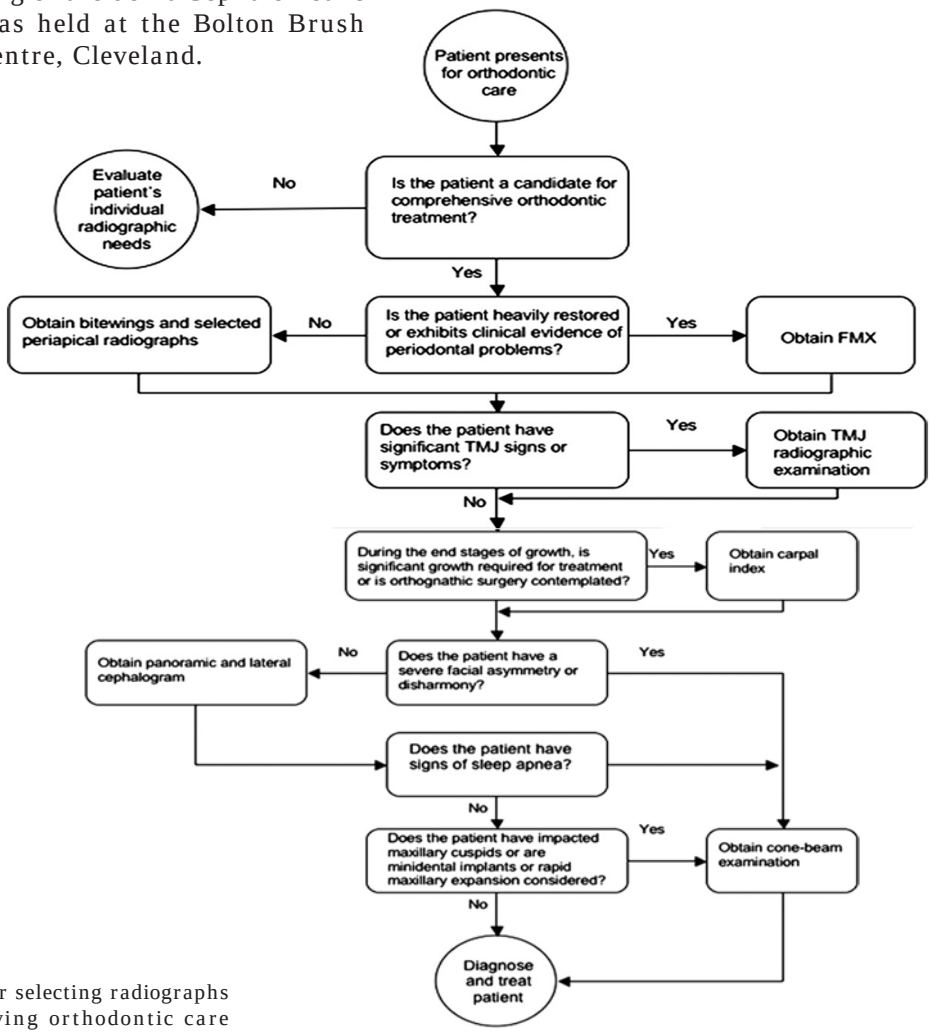

Figure 1: Algorithm for selecting radiographs for the patient receiving orthodontic care (Courtesy- Semin Orthod 2009; 15:19-28.[5])

Radiation consideration

Radiation exposure is hazardous to both patient and the dentist in any radiological process. The potential of cone beam scanners for collimating the primary x-ray to the region of interest allows for the reduction of radiation exposure.

Dentists and other medical professionals should follow the ALARA (As Low As Reasonably Achievable) protocol, so as to expose the patients to the least amount of radiation possible while still gaining the most information for proper diagnosis.[6] Dose comparison for various imaging modalities (Figure 2)

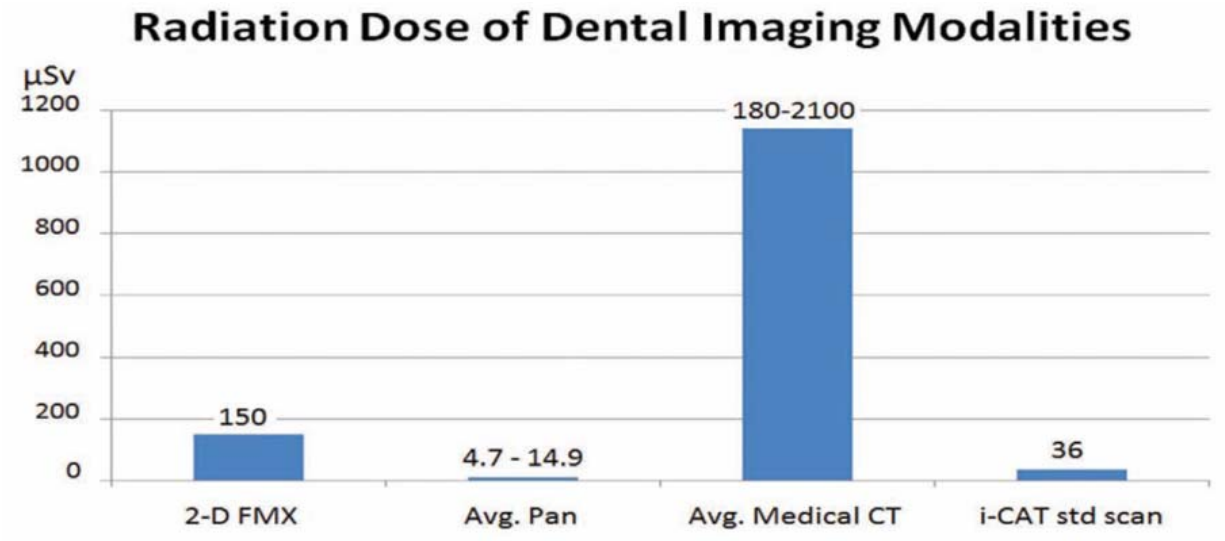

Figure 2: (Courtesy- Sedentexct, 2009).[7]

CLINICAL APPLICATIONS OF CBCT

Many applications are there for cone beam computer tomography, which is given below, from which few applications will be dealt in detail.[8,9,10]

1. Impacted canines & other impacted teeth.
2. Root resorption.
3. Fractured roots.
4. Cleft lip and palate.
5. Temporary anchorage device placement.
6. Asymmetry.
7. Airway assessment.
8. 3D cephalometrics.[11]
9. Dental measurements: overjet, overbite, arch width, arch length, mesiodistal tooth width.[12]
10. Tooth movement limits.
11. Morphometrics.
12. Dental development.
13. Facial growth.
14. Indirect bonding of brackets.
15. 3D construction of mandibular condyle.[13]
16. Tempormandibular joint degenerative changes.
17. 3D orthognathic surgery simulation using image fusion.[14,15]
18. 3D virtual models production.[16]
19. Assessment of root length & marginal bone level during orthodontic tooth movement.[17]

Impacted canines

The prevalence of impacted maxillary canines is approximately 0.9% to 3.0%. The ratio of palatal to labial impactions has been shown to be as high as 9:1.[18] CBCT is the advanced imaging technique in orthodontics for impacted canine evaluation. It precisely determines not only the labial/lingual relationship but also a more exact angulation of the impacted canine. which will aid the orthodontist in planning the treatment for impacted canine.

Other impacted tooth

Other teeth like maxillary central incisor which can be impacted and displaced due to the presence of a mesiodens.[18] This knowledge can help determine whether to retain or place traction on these impacted teeth.

Root resorption

Root resorption during orthodontic treatment can be viewed on periapical radiographs. Resorption that occurs on the facial or lingual side of the tooth is difficult to identify with this 2D view. CBCT scanning allows for better viewing of resorption on either of these surfaces.[19] Apart from that CBCT imaging helps in determining maxillary canine eruption position and its possible relationship with future resorption of the adjacent lateral and central incisor.

Cleft lip & Palate

Cleft lip and cleft palate are the most common developmental craniofacial anomalies.[19] The rapid acquisition time is the major advantage for young patients. In addition, the image quality is generally superior to that medical CT. CBCT provides information of osseous defect in great detail for surgical treatment planning.

Temporary anchorage device placement

The temporary anchorage device (TAD) has gained popularity in the field of orthodontics.[20] The knowledge of the root position and the quality of the bone in the proposed placement sites can greatly enhance the opportunity for proper placement and success of TADs.These images allow clinicians as to decide exact location of placement of TADs during orthodontic treatment.[21]

Asymmetry evaluation

Determination of an asymmetric maxilla or mandible can be accomplished more easily by CBCT. Orthodontist can view these structures in various angulations using the data taken in only one scan instead of using numerous 2D radiographic views.

Soft tissue

The soft tissue data gathered in the CBCT scan, it is possible to rotate and tilt the head in numerous positions to evaluate symmetry of the soft tissue.In addition it is also used for determining the relationship of soft tissue to facial skeleton for planning tooth movement and orthognathic surgeries.

Airway

Using lateral cephalometric radiographs, the orthodontist may evaluate the airway in a 2D manner but a 3D view of the airway can be readily available with CBCT imaging which allows to determine the depth and width of the airway.[22]

Advantages of cone-beam CT

The use of CBCT technology in clinical dental practice has a number of advantages:

Rapid scan time

CBCT captures all images in a single rotation, scan time in comparison to panoramic radiography is fast, and time for data reconstruction however is longer; it may range from approximately 1 minute to 20 minutes.

Beam limitation

Collimation of the primary x-ray beam enables limitation of the radiation to the field of interest, suspected disease presentation.

Image accuracy

CBCT produces images with good resolution accurate enough for measurement in maxillofacial applications,[23] such as implant site assessment and orthodontic treatment planning.

Reduced patient radiation dose

Radiation dose for various CBCT devices ranges from 29 to 477 mSv, depending on the type and model of CBCT equipment and FOV selected.[6] It reduces the patient radiation dose to (5 - 74) times that of a single film-based panoramic X rays .On the whole dose reductions of between 98.5% and 76.2% can be achieved.

Interactive display modes

CBCT technology reconstruct the projection data to provide images in three orthogonal planes (axial, sagittal, and coronal). Reconstruction of CBCT data is performed using a personal computer, data can be reoriented. With some basic enhancements like magnification, window/level.

Limitations of cone-beam CT imaging

CBCT technology has limitations related to the ''cone-beam'' projection geometry, detector sensitivity, and contrast resolution that produces images with lack of clarity.

Artifacts

An artifact is any distortion or error in the image that is unrelated to the subject being studied.

Patient-related artifacts

Patient motion can cause misregistration of data, which appears as unsharpness in the reconstructed image. The presence of dental restorations in the FOV can lead to severe streaking artifacts, resulting in horizontal streaks in the image.

Scanner-related artifacts

Scanner-related artifacts present as circular or ring-shaped, resulting from imperfections in scanner detection or poor calibration.

Cone beam -related artifacts

Three types of cone-beam-related artifacts are there:

(1) Partial volume averaging,

(2) Undersampling,

(3) Cone-beam effect.

Partial volume averaging.

It is seen when the selected voxel resolution of the scan is greater than the spatial or contrast resolution of the object to be imaged. Boundaries in the resultant image may present with a ''step'' appearance or homogeneity of pixel intensity levels, (eg, seen in the temporal bone scan).

Undersampling.

Undersampling can occur when very few basis projections are provided for the image reconstruction. A reduced data leads to misregistration and sharp edges and noisier images, where fine striations appear in the image.

Cone-beam effect.

Seen, especially in the peripheral portions of the scan volume due to the divergence of the x-ray beam as it rotates around the patient in a horizontal plane, results in image distortion, streaking artifacts, and greater peripheral noise.

Image noise

When large volume is being irradiated, a large portion of the photons engage in interactions by way of attenuation. Most of these occur by Compton scattering producing scattered radiation. This additional recorded x-ray attenuation, reflecting nonlinear attenuation, is called noise.

Poor soft tissue contrast

Factors like scattered radiation, image noise and divergence of the x-ray beam, leads to decrease in the contrast resolution of CBCT.

Conclusion

CBCT technology is beneficial to both patients and practitioners, it provides clinicians with good resolution images of high diagnostic quality with relatively short scanning times (10 -70 seconds) and low radiation dose. It is especially important to orthodontic field because of its ability to capture the entire anatomy needed for orthodontic treatment planning. When used correctly, the data derived from CBCT imaging provides information for treatment planning that is more accurate when compared with other imaging methods, and allows clinicians to provide better results.

REFERENCES

1. David L Way. Utilization of CBCT in an Orthodontic Practice. The Summer 2006 AADMRT Newsletter.
2. Mark G, Valithan M, Palomo JM. A link with past, a promise for future. Semin Orthod 2011; **17**;81-87.
3. Farman A and Scarfe WC. The basics of maxillofacial cone beam computed tomography. Semin Orthod 2009;**15**:2-13.
4. Scarfe WC, Farman AG. What is cone beam CT and how does it work. Dent Clin N Am. 2008;**52**: 707-730.
5. Stuart C. White and Pae EK. Patient Image Selection Criteria for Cone Beam Computed Tomography Imaging. Semin Orthod. 2009; **15**:19-28.
6. Alves M, Silva G, Wolf U, Heinicke F, Bumann A,Visser H and Hirschf E. Cone-beam computed tomography for routine orthodontic treatment planning: A radiation dose evaluation. Am J Orthod Dentofacial Orthop. 2008; **133**:640.e1-640.e5.
7. Radiation doses and risks of CBCT. http:// www.sedentexct.eu/content/radiation doses and risks-cbct.
8. Steven L. Applications in Orthodontics. Dent Clin N Am. 2008;**52**: 809-823.
9. James K, Huang JC. Practical applications of CBCT in orthodontics. Jam Dent Assoc 2010;**141**(3):7S-13S.
10. White SC, Pharoah MJ. The evolution and application of dental Maxillofacial imaging modalities. Dent Clin N Am. 2008;**52**: 689-705.
11. Kaua CH and Richmond S. Three-dimensional analysis of facial morphology surface changes in untreated children from 12 to 14 years of age. Am J Orthod Dentofacial Orthop. 2008;**134**:751-60.
12. Creed B, Kau CH, English JD, Xia J, and Robert P L, A Comparison of the Accuracy of Linear Measurements Obtained from Cone Beam Computerized Tomography Images and Digital Models. Semin Orthod 2011;**17**:49-56.
13. Schluetera B, Kimb K. Cone Beam Computed Tomography 3D Reconstruction of the Mandibular Condyle. Angle Orthodontist. 2008;**78**(5):110-115.
14. Kau CH, Olim S. The future of orthodontic diagnostic records. Semin Orthod. 2009;**15**(17):39-45.
15. Stephen A, Schendel and Chris Lane. 3D Orthognathic Surgery Simulation Using Image Fusion. Semin Orthod. 2009;**15**:48-56.
16. William E Harrell Jr. 3D Diagnosis and Treatment Planning in Orthodontics. Semin Orthod. 2009;**15**:35-41.
17. Lunda H, Grondahla K. Cone Beam Computed Tomography for Assessment of Root Length and Marginal Bone Level during Orthodontic Treatment. Angle Orthod. 2010; **80**:466 -473.
18. Tamimi D and ElSaid K. Cone beam computed tomography in the assessment of dental impactions, Semin Orthod 2009; **15**:57-62.
19. Kang BC, Yoon SJ, Lee J. The use of cone beam computed tomography for the evaluation of pathology, Developmental anomalies & traumatic injuries relevant to orthodontics. Semin Orthod 2011;**17**:20-33.
20. Liu H, Liu D, Wang G. Accuracy of surgical positioning of orthodontic miniscrews with a computer-aided design and manufacturing template. Am J Orthod Dentofacial Orthop. 2010;**137**:728.e1-728.e10.
21. Park J and Cho HJ. 3D evaluation of interradicular spaces and cortical bone thickness for the placement and initial stability of micro implants in adults. Am J Orthod Dentofacial Orthop. 2009;**136**:314.e1-314.e12.
22. Grauer, Lucia SH, Cevindanes L, Ackerman J, Proffit WR. Pharyngeal airway volume and shape from cone -beam computed tomography: Relationship to facial morphology. Dan Am J Orthod Dentofacial Orthop. 2009;**136**:805-814.
23. Gribela BF, Gribelb MN. Accuracy and reliability of craniometric measurements on lateral cephalometry and 3D measurements on CBCT scans. Angle Orthod. 2011; **81**:26-35.