

Classification of Food Impaction - Revisited and its Management

Mayur Khairnar¹

Quick Response Code



doi: 10.5866/2013.51113

¹Periodontology & Impalntology,
Private practice, Mumbai.
Precision Dental Clinic & implant Center,
Near K.T.Multiplex, Anand Nagar,
Vasai Road (west) - 401202, Thane,
Maharashtra. India.

Article Info:

Received: October 13, 2012;
Review Completed: November 12, 2012;
Accepted: December 11, 2012
Available Online: March, 2013 (www.nacd.in)
© NAD, 2013 - All rights reserved

Email for correspondence:
drmayurkhairnar@gmail.com

INTRODUCTION:

The phrase '**form follows function**' reflects a concept of inter-relating the shape with its function. In dentistry, the phrase indicates the entire masticatory function, acting as biomechanical system for the reduction of food. The form of teeth and their position and arrangement in jaws are related to inscing or crushing food (i.e... mastication) without causing damage to its supporting structures. But however, any alteration in form of teeth can bring variation in its function which may induce injury to periodontium also. This review discusses normal and various altered form of teeth and its relationship with food impaction, and methods of prevention of food impaction.

Role of natural embrasures in prevention of food impaction:

When two teeth in the same arch are in contact, their curvatures adjacent to the contact areas forms embrasures, also known as spillway spaces.

The spaces that widen out from the contact area labially or buccally and lingually are called labial or buccal and lingual interproximal embrasures. These embrasures are continous with the interproximal spaces between the teeth. (Fig 1)

ABSTRACT:

Food impaction is forceful wedging of food into the periodontium. Continuous impaction food leads to localized periodontitis, periodontal abscess and even carious lesion. Any minor deflection in any occlusal scheme can cause food impaction. (Now a day there is greater negligence towards finding of food) impaction and it plays crucial role in progression of root carious lesion and periodontal disease. Also if one fails to find its presence, failure of periodontal therapy is unavoidable. Hence it is very important for the clinicians to evaluate its presence and carry necessary step to relieve it before commencing other treatment. This review explains the mechanism of food impaction and its management.

Key words: Food impaction, Pain, Periodontitis, Inter-Proximal contact, Root caries.

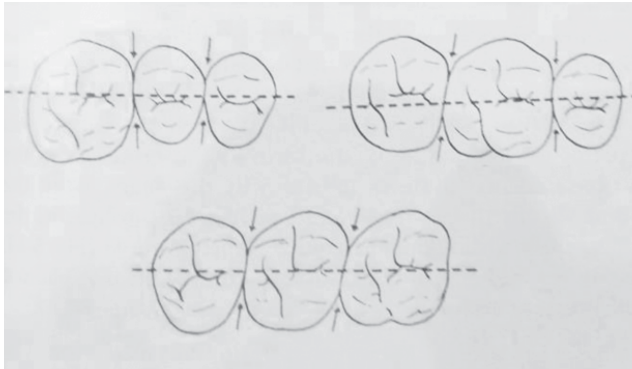


Fig 1: Arrow indicates Buccal or Lingual embrasures.

Above the contact areas incisally and occlusally, the spaces, which are bounded by marginal ridges they join the cusps and incisal ridges, are called incisal or occlusal embrasures. (Fig 2)

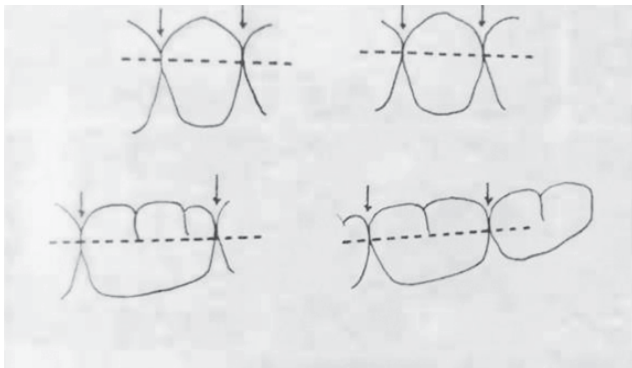


Fig 2: Arrow indicates incisal or occlusal embrasures.

The curved proximal surfaces of the contacting teeth roll away from the contact area at all points, occlusally or incisally, labially or buccally and lingually and cervically, and the embrasures and interproximal spaces are continuous, as they surrounds the area of contact.

The form of embrasures serves three purposes:

- 1) Provides spillways for food during mastication,
- 2) Provides physiological form that reduces forces brought to bear on the teeth during grinding of any food material that offers resistance;
- 3) Prevents food from being forced through the contact area.

What is food impaction?

Food impaction is the forceful wedging of food into the periodontium by occlusal force. It may occur interproximally or in relation the facial or lingual tooth surfaces. Food impaction is a very common

cause of gingival and periodontal disease. Failure to recognize and eliminate food impaction results in unsuccessful outcome periodontal therapy performed in the region. Food impaction is distinct from food lodgment, later being just a mere lodgment of food particle, which get washed away even after normal mouth rinsing.

Mechanism of food impaction:

(Fig 3 - Vertical Food Impaction & Fig 6 - Horizontal Food Impaction)

The forceful wedging of food normally is prevented by the

- Integrity and location of proximal contact,
- The contour of the marginal ridge and developmental grooves, and
- The contour of the facial and the lingual surfaces.

An intact and firm proximal contact relationship precludes the forceful wedging of food interproximally. The location of the contact is also important in protecting the tissues against food impaction The optimum cervico-occlusal location of the posterior contact area is at the longest mesiodistal diameter of the generally just apical to the crest of marginal ridge. The proximity of the contact point to occlusal plane reduces the tendency toward food impaction in the smaller occlusal embrasures. The absence of contact or presence of unsatisfactory proximal relationship is conducive to food impaction. The contour of occlusal surface established by the marginal ridges and related developmental grooves normally serves to deflect food from interproximal spaces. (Fig 3)

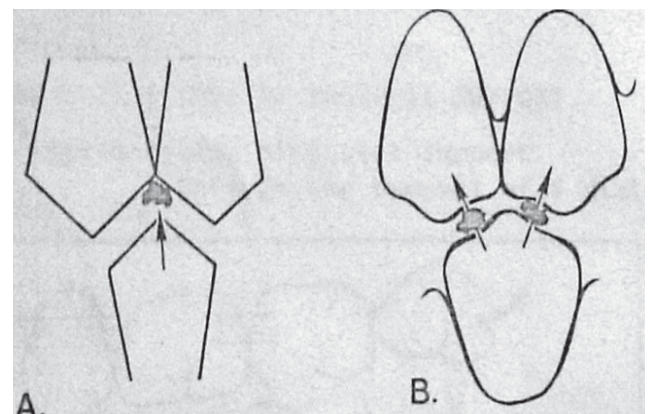


Fig 3 - Role of contour of marginal ridge in prevention of food impaction.

A. Flattened contour leads to food impaction.

B. Normal contours avoids it by deflecting the food away from interproximal space.

As the teeth wears down and flattened surfaces replace the normal convexities, the wedging effect of opposing cusp is exaggerated, and food impaction results. Cusps that tend to forcibly wedge food into interproximal embrasure are known as plunger cusps. The plunger cusp effect may occur with wear as indicated above, or may be the result of a shift in tooth position following failure to replace missing teeth.

Common areas of food impaction:

1. Vertical impaction :

A. Open contacts

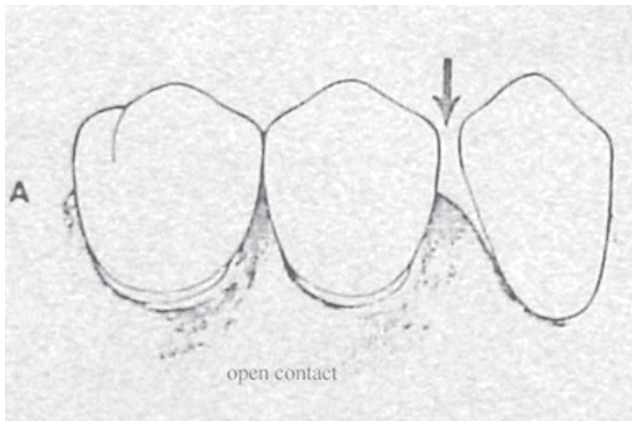


Fig 4: Food impaction due to Open contacts

B. Irregular marginal ridge

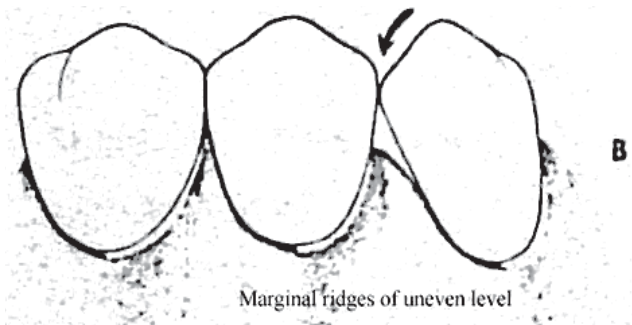


Fig 5: Food impaction due to Irregular marginal ridge

Food impaction associated with open contact causes more probing depth and clinical attachment loss interproximally than that associated with uneven marginal ridge.¹

C. Plunger cusp: Cusp that tend to forcibly wedge food interproximal region of opposing teeth.

1. Causes: occlusal wear, shift in tooth position
2. Horizontal (lateral) food impaction-(Fig 6)

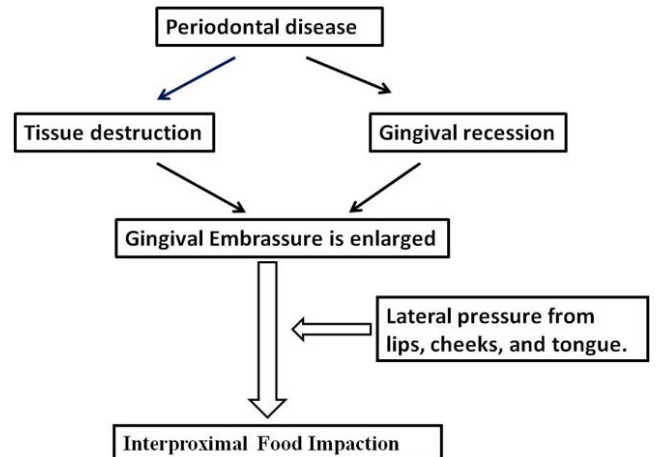


Fig 6: Mechanism of Action of Lateral Food Impaction

Hirschfeld² (1930) have documented several conditions and factors responsible for food impaction and gave classification of factors causing food impaction as follows:

Classification of Factors Causing Food Impaction

- Class I: Occlusal wear
- Class II: Loss of proximal contact
- Class III: Extrusion beyond the occlusal plane
- Class IV: Congenital morphological abnormality
- Class V: Improperly constructed restorations

1. **CLASS I : Occlusal wear**

A. **Type A:** Wedging action produced by transformation of occlusal convexities into oblique facets, exaggerating the action of plunger cusp. (Fig7)

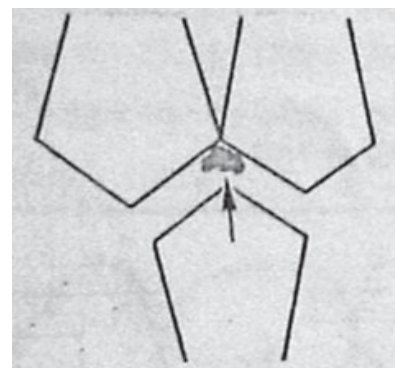


Fig 7: Class I type A Food Impaction.

B. Type B: Remaining obliquely worn cusp of a maxillary tooth overhanging the distal surface of its functional antagonist. (Fig 8).

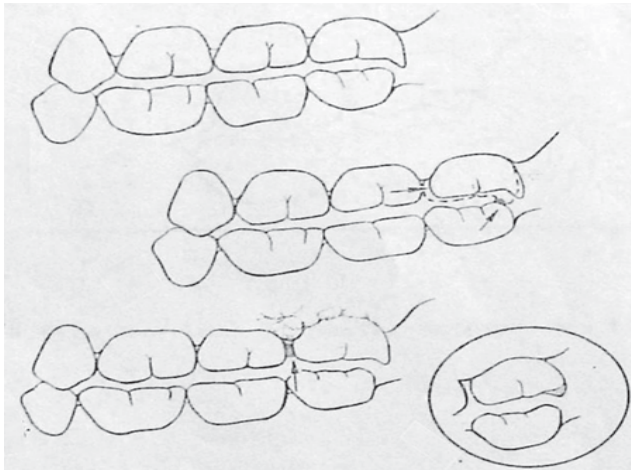


Fig 8: Class I type B Food Impaction

When the Cusp of maxillary tooth overhanging the distal surface of mandibular tooth, in such case maxillary tooth is forced distally by occlusal forces and bolus of the food, destroying the mesial proximal contact and favours food impaction.

C. Type C : Obliquely worn mandibular tooth overlapping the distal surface of its functional antagonist (Fig 9)

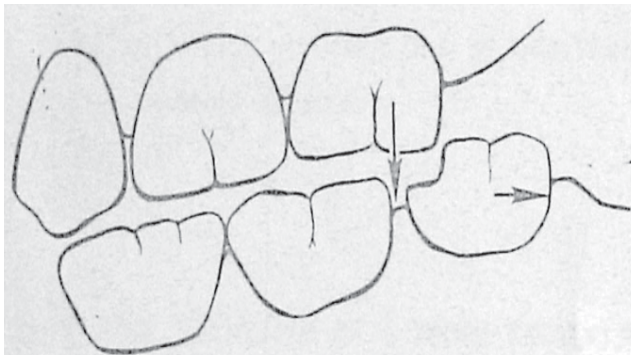


Fig 9: Class I type C Food Impaction

When there is attrition of the mesial portion of the crown of the mandibular molar and it is overlapping the distal surface of maxillary molar, due to functional relationship mandibular molar is forced distally thus creating open contact at mesial aspect. thus favouring food impaction mesial to mandibular molar.

2. CLASS II : Loss of proximal support

Type A: Loss of distal support through the removal of a distally adjacent tooth. (Fig 10.)

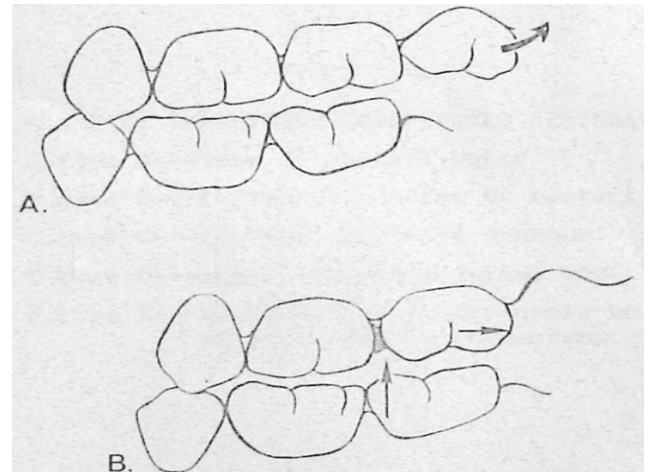


Fig 10: Class II type A Food Impaction.

Extraction of molar results in loss of proximal support which causes gradual shifting of adjacent teeth into extraction space, thus creating open proximal contact distal to distal tooth and mesial to mesial tooth.

Eg: Maxillary molar may be forced distally by functional forces in the absence of maxillary third molar. This may results into food impaction between maxillary first and second molars (i.e. mesial to second molar). (Fig 10)

Type B: Loss of mesial support due to extraction of mesial tooth. (Fig 11)

Type C: Oblique drifting due to non-replacement of a missing tooth. (Fig 11)

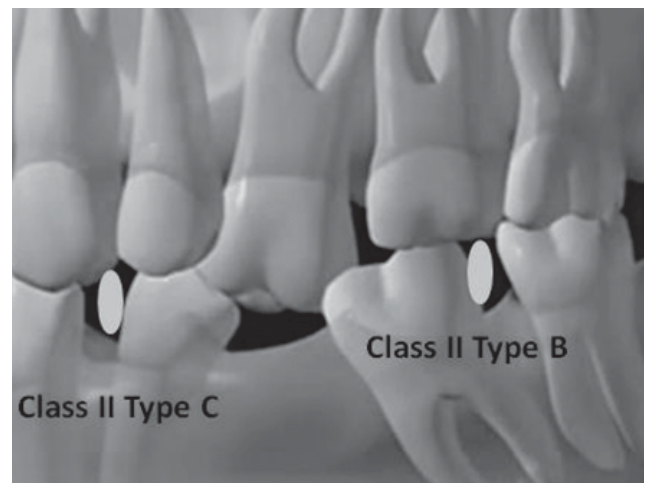


Fig 11: Class II Type B & C Food Impaction.

Non replacement of missing tooth results into space loss by drifting of mesial and distal tooth and extrusion of antagonist tooth into the missing teeth

space. This opens-up proximal contact relationship and favors food impaction.

Type D: Permanent occlusal openings to interdental spaces. (Fig: 4)

- i. Drifting after extraction.
- ii. Habits forcing teeth out of position.
- iii. Periodontal disease.
- iv. Caries.

3. CLASS III : Extrusion beyond the occlusal plane:

Extrusion of a tooth which was previously retaining contiguity with the adjacent mesial and distal teeth result in occlusal step deformity between marginal ridges of extruded and non-extruded teeth. Thus disturbing proximal contact relationship and favouring food impaction.

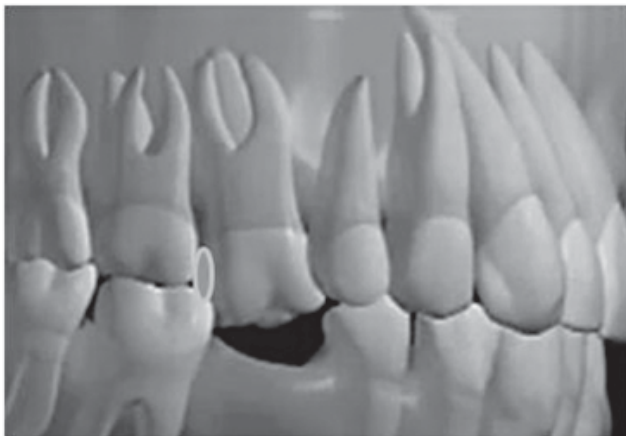


Fig 12: Class III Food Impaction

4. CLASS IV: CONGENITAL MORPHOLOGIC ABNORMALITIES

Any congenital morphologic abnormalities in size, shape, form and position of tooth leading to open proximal contact, is conducive to food impaction.

Type A: position of a tooth in torsion.

Position of tooth in torsion indicates tooth with buccal rotation. Most commonly found buccally rotated teeth are premolars with buccal surface facing mesially and lingual surface distally. In such case, due to inclined plateau of occlusal surface of premolar food get directed into the distal interproximal space.

Type B: emphasized embrasure between thick-neck teeth.

Type C: facio-lingual tilting.

Tilting of the tooth either facially or lingually can alter interproximal relationship with adjacent teeth, permitting food impaction.

Type D: Lingual or Buccal position of the tooth.

Positioning of the tooth much buccally or lingually (anterior cross bite) can also induce food impaction.

5. CLASS V: IMPROPERLY CONSTRUCTED RESTORATION.

Type A: Loss of contact point in restoration.

Failure to restore contact point or area in any restoration or prosthesis allows passage of food into interproximal periodontium under the influence of plunger cusp causing further destruction.

Type B: Improper location of contact point.

Establishing contact too occlusally will create a smaller occlusal embrasure space. This will prevent food from escaping interproximal region and action of plunger cusp will force the food into interproximal periodontium.

Establishment of contact point too gingivally will induce inflammatory response in interdental papilla region leading to bone loss.

Type C: Improper occlusal contour.

Establishment of improper flat interproximal contour will have inappropriate contact relationship and soon or later will develop food impaction due to faulty restoration design.

Type D: Improperly constructed cantilever restorations

Type E: Scalloped cervical bevels on the tissue-borne areas of prosthetic restorations:

Scalloped cervical bevels on margins of prosthetic crown can be evaluated by running an explorer along the margins of the prosthesis. Usually, if prosthesis margins are over contoured at mesial and distal aspect, it may induce periodontitis, leading to loss of interproximal bone support.

Jung JH et al³ in clinical study on the occurrence of food impaction evaluated following results:

1. Teeth without distal support were found to be the most frequent site of food impaction (41.6%).
2. Food impaction was found to be more frequent in the upper teeth (66.2%) than the lower teeth (33.8%).
3. Food impaction was found in tight contact cases (71.4%). Alveolar bone loss was not found in the early stage of food impaction (83.1%).
4. The distance between the marginal ridges of food impaction sites (mean=0.48mm) was shorter than that of the control group.
5. In 18.2% of the cases, proximal carries were found at the food impaction site.
6. Food impaction affected patient's occlusion with the following frequencies; cusp to marginal ridge relationship (72.7%), cusp to fossa relationship (3.9%) and stepped relationship (23.4%).

Sequel of Food Impaction:

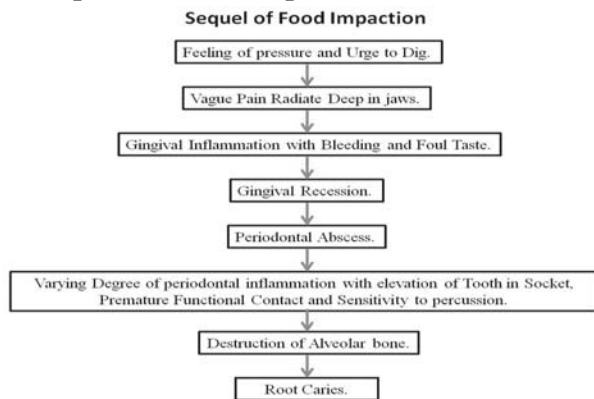


Fig 13: Sequel of Food Impaction:

Signs & Symptoms:

1. DISCOMFORT

- A. Feeling of pressure
- B. Vague pain
- C. Root caries

2. PERIODONTAL CHANGES

- A. Gingival inflammation-bleeding & foul taste
- B. Gingival recession
- C. Periodontitis

D. Periodontal abscess formation

E. Alveolar bone loss - vertical

Prevention and Treatment:

1. **PERIODONTAL TREATMENT** : Scaling and root planing, flossing / interproximal brushing, curettage, etc
2. **OCCLUSAL ADJUSTMENT:**
 - A. **Plunger cusp:** Round these sharp peaks of plunger cusp. These plunger cusp are usually the functional cusp (i.e. palatal cusp of maxillary teeth and buccal cusp of mandibular teeth) and sometimes palatal incline of maxillary buccal cusp & buccal incline of lingual cusp. Examination of the study cast for the evaluation of lingual cuspal relationship may provide additional benefits. (Fig 14)

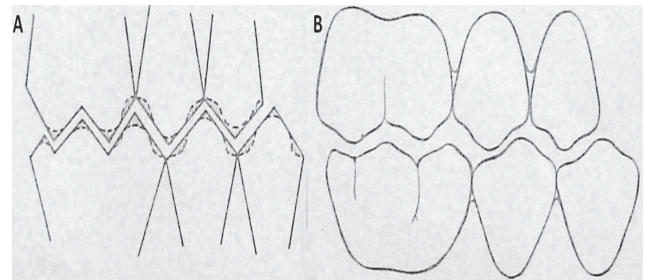


Fig 14: Occlusal Adjustment of Plunger Cusps. (A) Before. (B) After. Dotted Line shows proposed anatomy of tooth.

B. Level the occlusal height of the marginal ridges

- i. Leveling of occlusal height of the marginal ridge can be done by either restoring it to previous level or by grinding it to favourable anatomy. Whether to restore or grind depends on following.

1. Relationship of the tooth with opposing tooth structure and to the overall plane of occlusion.




Fig 15: Occlusal Adjustment uneven Marginal Ridge relation.

2. Degree of discrepancy. Extrusion is associated with discrepancy in marginal ridge relationship. If extrusion is less, discrepancy can be managed simply by grinding. But if extrusion is greater, restoration with prosthesis is required to correct marginal ridge discrepancy.
3. Iatrogenic hazards- grinding and carving of marginal ridge on severely worn attrited tooth may increase chances of pulp exposure, causing iatrogenic damage. Hence, recarving of the marginal ridge by restoration is ideal in attrited tooth.
 - ii) Consider the slope of the marginal ridge (external, internal) while restoring discrepancy in the marginal ridge relationship. Internal slope of marginal ridge allows food escape in favourable direction while external slope of marginal ridge forms occlusal embrasure, prevents food from being forced into contact area. When a marginal ridge is being leveled, the proximal fossa is generally obliterated, the fossa must be recarved. (Fig 16)

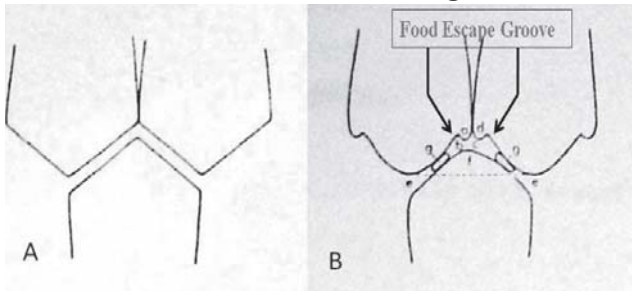


Fig 16: Adjusting occlusal height of the marginal ridges.

- C. Grooves and fossa
 - i. Recarve obliterated or missing fossa.
 - ii. Distinct, but shallow, saucer-shape fossa mesially and distally with slightly extended grooves (spillway or sluiceways)
 - iii. To deflect food from interproximally to buccally or lingually

Newell DH et al⁴ suggested creating food escape groove adjacent to marginal ridge prevent food impaction in tight contact area. (Fig 16)

3. RESTORING AN IDEAL CONTACT: An intact, firm proximal contact relationships prevents the forceful wedging of food inter-proximally - Protect interdental papilla.

It can be brought either by restoration or orthodontic tooth movement.

- A. Ideal contact: Contact area must be evaluated thoroughly by its Location, Width, Height, and Tightness.
- B. Contact tightness must be check carefully with dental floss.
4. PERMANENT RESTORATION
 - A. Factors should be know in permanent restoration
 - i. Proximal contact.
 - ii. Contour of occlusal surface.
 - iii. Facial & lingual contour.

If restored crown or filling fails to relieve Food Impaction, it may cause Class V Food Impaction.

Conclusion:

Food Impaction often makes a feeling of urgency to dig into an affected area. Very often it is seen that patient momentarily feel relieved of pain after using tooth pick in gingivo-occlusal direction. But this does not solve the problem of subsequent food impaction and its Sequelae. Also, just merely restoring the contact area without evaluating the any non harmonious occlusal contacts does not relieve Food Impaction.

Hence it is very necessary to find the factor responsible for Food impaction. This detailed Classification helps to determine the etiologic factor responsible for Food impaction.

References:

1. Jernberg G, Bakdash B, Keekan K: Relation between proximal tooth open contact and periodontal diseases. J periodontal 1983; **54**:529.
2. Hirschfeld I: Food Impaction. J Am Dent Asso. 1930; **17**:1504.
3. Jung JH, Oh SC, Dong JK: A Clinical Study on the Occurrence of Food Impaction. J Korean Acad Prosthodont. 2000; **38**:50-58.
4. Newell DH, John V, Kim SJ.: A technique of occlusal adjustment for food impaction in the presence of tight proximal contacts. Oper Dent. 2002; **27**:95-110.